



Influence of buccal bone wall thickness on the peri-implant hard and soft tissue dimensional changes: A systematic review

Alberto Monje^{1,2,3}  | Andrea Rocuzzo^{3,4}  | Daniel Buser⁵ | Hom-Lay Wang¹

¹Department of Periodontology and Oral Medicine, University of Michigan, Ann Arbor, Michigan, USA

²Department of Periodontology, Universitat Internacional de Catalunya, Barcelona, Spain

³Department of Periodontology, University of Bern, Bern, Switzerland

⁴Department of Oral Maxillofacial Surgery, Copenhagen University Hospital (Rigshospitalet), Copenhagen, Denmark

⁵School of Dental Medicine, University of Bern, Bern, Switzerland

Correspondence

Alberto Monje, Department of Periodontology, Universitat Internacional de Catalunya, C/ Josep Trueta s/n, 08195 - Sant Cugat del Vallès, Barcelona, Spain.
Email: amonjec@umich.edu



International Team
for Implantology

Abstract

Background: The significance on the association between the peri-implant buccolingual dimension (BLD) at the stage of implant placement and the occurrence of biological and esthetic complications is yet unknown.

Material and methods: Systematic screening of electronic sources was carried out to identify clinical and preclinical studies reporting on the baseline BLD and/or buccal bone thickness (BBT) values. A secondary objective was to assess the effect of simultaneous grafting at sites with deficient or no buccal bone wall (BBW) at baseline. The primary outcome variables were BBT, BLD, and buccal vertical bone loss (VBL) at re-evaluation. Moreover, radiographic, clinical, and patient-reported outcome measures (PROMs) were evaluated.

Results: Overall, 12 clinical and four preclinical studies met the inclusion criteria. Inconsistencies were found in defining the critical BBT across the clinical and preclinical data evaluated. The clinical evidence demonstrated that during healing, dimensional changes occur in the alveolar bone and in the BBW that may compromise the integrity of the peri-implant bone, leading to VBL and mucosal recession (MR), particularly in scenarios exhibiting a thin BBW. The preclinical evidence validated the fact that implants placed in the presence of a thin BBW, are more prone to exhibit major dimensional changes and VBL. Moreover, the clinical data supported that, in scenarios where dehiscence-type defects occur and are left for spontaneous healing, greater VBL and MR together with the occurrence of biologic complications are expected. Furthermore, the augmentation of dehiscence-type defects is associated with hard and soft tissue stability. PROMs were not reported.

Conclusions: Dimensional changes occur as result of implant placement in healed ridges that may lead to instability of the peri-implant hard and soft tissues. Sites presenting a thin BBW are more prone to exhibit major changes that may compromise the integrity of the buccal bone and may lead to biologic and esthetic complications.

KEYWORDS

biomaterials, bone implant interactions, bone regeneration, guided tissue regeneration, peri-implantitis, peri-implant disease

1 | INTRODUCTION

Implant failures due to biological complications or unsatisfactory esthetic outcomes very often originate from implant malpositioning or errors during implant surgery (Monje et al., 2016). Interestingly, peri-implantitis and esthetic failures are more commonly noted in the buccal aspects (Monje & Nart, 2022). Implants placed in healed sites must have an adequate buccal bone wall thickness (BBW) to ensure that the implant is circumferentially embedded in vital bone at the completion of bone healing. Once initial bone healing and remodeling have taken place, the entire micro-rough implant surface must be osseointegrated and circumferentially covered by vital bone (Spray et al., 2000).

It is known that the outer layer of the buccal bone wall (BBW) is predominantly composed of cortical bone, which receives most of its vascular blood supply from the outside (the periosteum) and from the inside (the endosteum; Roush et al., 1989). The central portion of the alveolar ridge is characterized by cancellous bone with a good blood supply. When a flap is raised to gain access for implant placement, the blood supply from the periosteum is interrupted. In addition, by inserting the implant into the prepared implant bed, the endosteal blood supply is interrupted as well, when the buccal bone wall is mainly comprised of cortical bone. The interruption of the blood supply from the outside as well as from the inside results in necrosis of the buccal bone. This process is called “avascular necrosis” (Mankin, 1992) and leads to vertical bone loss (VBL), most often on the buccal aspect of the implant (Monje et al., 2019). This contributes to exposure of the micro-rough implant surface into the peri-implant sulcus, and consequently into the oral cavity—facilitating the potential access of bacteria and the perpetuation of pathological conditions (Roux & Orsel, 2000), as well as mucosal recession that leads to an unpleasing esthetic appearance (Monje et al., 2019). In consequence, the exposed micro-rough implant surface becomes a significant risk factor for biological complications as it can be set as the niche for pathogenic bacteria.

It has been suggested that dehiscence-like bone defects resulting from previous unsuccessful regenerative procedures (Schwarz et al., 2012) or during implant placement in pristine alveolar bone (Jung et al., 2017) may lead to instability of the soft and hard peri-implant tissues, resulting in a greater risk of developing biological complications (Monje et al., 2016). In fact, the presence of a thin BBW, often conditioned by the implant position (Grunder et al., 2005), has been shown to be related to a greater risk of peri-implant bone resorption during initial healing—resulting in a greater susceptibility to develop unfavorable peri-implant conditions (Monje et al., 2019), including mucosal recession (Farronato et al., 2020), peri-implantitis (Monje et al., 2019) and eventually implant failure (Spray et al., 2000). In contrast, one clinical study reported that alveolar bone dimensions did not show a negative impact on clinical and radiographic outcomes at 3-year follow-up (Temmerman et al., 2015). Considering the above, the aim of the present systematic review was to shed light on the influence of critical BBT and the overall dimensions of alveolar bone upon soft and hard tissue

stability and to thus assess the need for simultaneous bone augmentation procedures according to the residual BBW. Findings derived from the present systematic review may assist in providing a clinical practice in implant dentistry more predictable in preventing esthetic and biological complications.

2 | MATERIAL AND METHODS

The study protocol was registered and received identification number CRD42021288604 in the PROSPERO International Prospective Register of Systematic Reviews, hosted by the National Institute for Health Research, University of York, Centre for Reviews and Dissemination.

Focused question 1: What is the peri-implant critical BBT that may compromise bone integration at the buccal aspect of dental implants placed in healed ridges?

2.1 | PECO question 1 for clinical research

- Patient: Partially or completely edentulous patients
- Exposure: Dental implants placed in native healed ridges exhibiting thin BBW or lack of BBW
- Comparison:
 - Comparison₁: Thick BBW
 - Comparison₂: Presence of BBW
- Outcome:
 - Outcome_{primary}: VBL
 - Outcome_{secondary (1)}: BBT, BLD changes, and
 - Outcome_{secondary (2)}: Peri-implant proximal bone level
 - Outcome_{secondary (3)}: Peri-implant clinical parameters, clinical health and esthetics
 - Outcome_{secondary (4)}: Patient-reported outcome measures (PROMs)

Focused question 2: What is the effect in terms of dimensional, clinical, and radiographic outcomes of simultaneous bone augmentation in scenarios below the critical BBT in healed ridges?

2.2 | PICO question 2 for clinical research

- Patient: Partially or completely edentulous patients
- Intervention: Dental implants placed in native healed ridges exhibiting thin BBW or lack of BBW
- Comparison:
 - Comparison₃: Augmented BBW
- Outcome:
 - Outcome_{primary}: VBL
 - Outcome_{secondary (1)}: BBT, BLD changes, and
 - Outcome_{secondary (2)}: Peri-implant proximal bone level
 - Outcome_{secondary (3)}: Peri-implant clinical parameters, clinical health and esthetics

- Outcome_{secondary (4)}: Patient-reported outcome measures (PROMs)

2.3 | Eligibility criteria

Inclusion and exclusion criteria are listed in [Table 1](#). It should be noted that whenever a study included implants placed immediately in fresh extraction sockets and healed sockets, only data from the latter were retrieved and included in the analysis.

2.4 | The preferred reporting items for systematic reviews and meta-analyses (PRISMA)

For describing and summarizing the results of our review, use was made of the 27-item PRISMA (Preferred Reporting Items for Systematic Reviews and Meta-Analyses) statement (Page et al., 2021).

2.5 | Search strategy

Two independent reviewers (AM and AR) performed the manual search and read the title and abstract of the entries obtained from the literature search. After completing the screening process, both reviewers assessed the full-text version of potentially eligible studies and established a final article selection. Disagreements between the reviewers were resolved by open discussion. If no consensus could be reached, a third author (HLW) was consulted. Any missing information that could contribute to the systematic review was requested from the corresponding author(s) via e-mail.

2.6 | Information sources

An electronic search of three databases (MEDLINE via PubMed, the Cochrane Library of the Cochrane Collaboration, and the New York Academy of Medicine Grey Literature) was conducted for studies published up to November 2021 (included), without language or year restrictions. The search strategy combined MeSH terms and text words with Boolean operators (OR, AND) filtered by “humans” and

“animals” and sorted according to the most recent publications. For the PubMed database, the search terms applied were the following: (dental implant[MeSH Terms]) OR (abutment, dental[MeSH Terms]) OR (dental implantation, osseointegrated[MeSH Terms]) AND (implantation, osseointegrated dental[MeSH Terms]) OR (alveolar bone dimension[Title/Abstract]) OR (buccal bone[Title/Abstract]) OR (buccal bone thickness[Title/Abstract]) OR (critical buccal bone[Title/Abstract]) OR (facial bone[Title/Abstract]) AND (facial bone thickness[Title/Abstract]) AND (bone regeneration[MeSH Terms]) OR (bone augmentation[Title/Abstract]) OR (guided bone regeneration[Title/Abstract]) OR (bone reconstruction[Title/Abstract]) AND (bone dehiscence[Title/Abstract]) OR (alveolar bone loss[MeSH Terms]) OR (buccal bone level[Title/Abstract]) OR (facial bone level[Title/Abstract]) OR (peri-implant condition[Title/Abstract]) OR (peri-implant health[Title/Abstract]) OR (peri-implantitis[Title/Abstract]). In turn, the Cochrane database and the Grey Literature Database were screened for unpublished papers in the New York Academy of Medicine in accordance with the AMSTAR checklist. The list of references of the included studies and related review articles was further screened to check for additional relevant studies.

2.7 | Data extraction

The following data were extracted and recorded in duplicate by two independent reviewers (AM and AR): (1) citation and year of publication; (2) experimental group; (3) sample size; (4) BBT and/or BLD at baseline and at re-assessment; (5) method of assessment; (6) timing of assessment; (7) clinical and radiographic outcomes and; (8) take-home message.

2.8 | Risk of bias in individual studies

Methodological quality of the included observational studies (i.e., case series, prospective studies) was assessed based on the Newcastle-Ottawa Quality Assessment Scale for Cohort studies (Wells et al., 2014) while for RCTs, the risk-of-bias 2.0. tool was adopted (Sterne et al., 2019). With respect to animal studies, the SYRCLE's risk-of-bias tool was used (Hooijmans et al., 2014).

TABLE 1 Eligibility criteria for the systematic review.

Inclusion criteria	Exclusion criteria
Clinical single- or multiple-arm trials (CCT, RCT, CS)	Case reports (<10 cases)
Preclinical trials	In vitro research
Clinical, radiographic, histological and/or volumetric examination	Nonvalidated tools for examination
Baseline data on the buccal and/or alveolar bone dimension	Lack of data on the buccal/alveolar bone dimension
Baseline and follow-up data	Lack of baseline and/or follow-up data
Implants placed in healed ridges	Implants placed in fresh extraction sockets
Systemically healthy patients	Patients with disease conditions and/or heavy smokers (≥10 cigarettes/day)

3 | RESULTS

The PRISMA flowchart for literature selection is depicted in Figure 1. In summary, 1700 records were identified after duplicates were removed. Ninety of these records were assessed for full text. One more article was identified screening the references from included papers. Overall, 16 were included in the qualitative synthesis. Of these, 12 were human studies (Barone et al., 2015; Cardaropoli et al., 2006; Covani et al., 2004; Farronato et al., 2020; Jung et al., 2017; Li Manni et al., 2020; Marconcini et al., 2018; Nohra et al., 2018; Oda et al., 2021; Schwarz et al., 2012; Spray et al., 2000; Temmerman et al., 2015), while four were preclinical studies (Baffone et al., 2015; Bengazi et al., 2014; Monje et al., 2019; Vignoletti et al., 2019). The most frequent reason for exclusion based on the full-text evaluation was no baseline dimensional data or missing information ($n = 41$; Table 2). The heterogeneity of the sample across the included studies precluded the conduction of meta-analyses.

3.1 | Study and sample characteristics

3.1.1 | Clinical studies

The dominant study design was the prospective cohort (PC; Cardaropoli et al., 2006; Covani et al., 2004; Farronato et al., 2020; Nohra et al., 2018; Schwarz et al., 2012; Spray et al., 2000; Temmerman et al., 2015), followed by the randomized clinical trial (RCT; Barone et al., 2015; Jung et al., 2017; Li Manni et al., 2020; Marconcini et al., 2018; Table 3). Only one retrospective cohort (RC) study (Oda et al., 2021) was included. Overall, 3237 sites (implants) were included and evaluated. The vast majority of the studies tested dimensional changes under spontaneous healing, while two studies (Jung et al., 2017; Schwarz et al., 2012) further tested simultaneous guided bone regeneration (GBR) on deficient ridges. Moreover, two studies (Barone et al., 2015; Marconcini et al., 2018) compared alveolar bone changes according to the

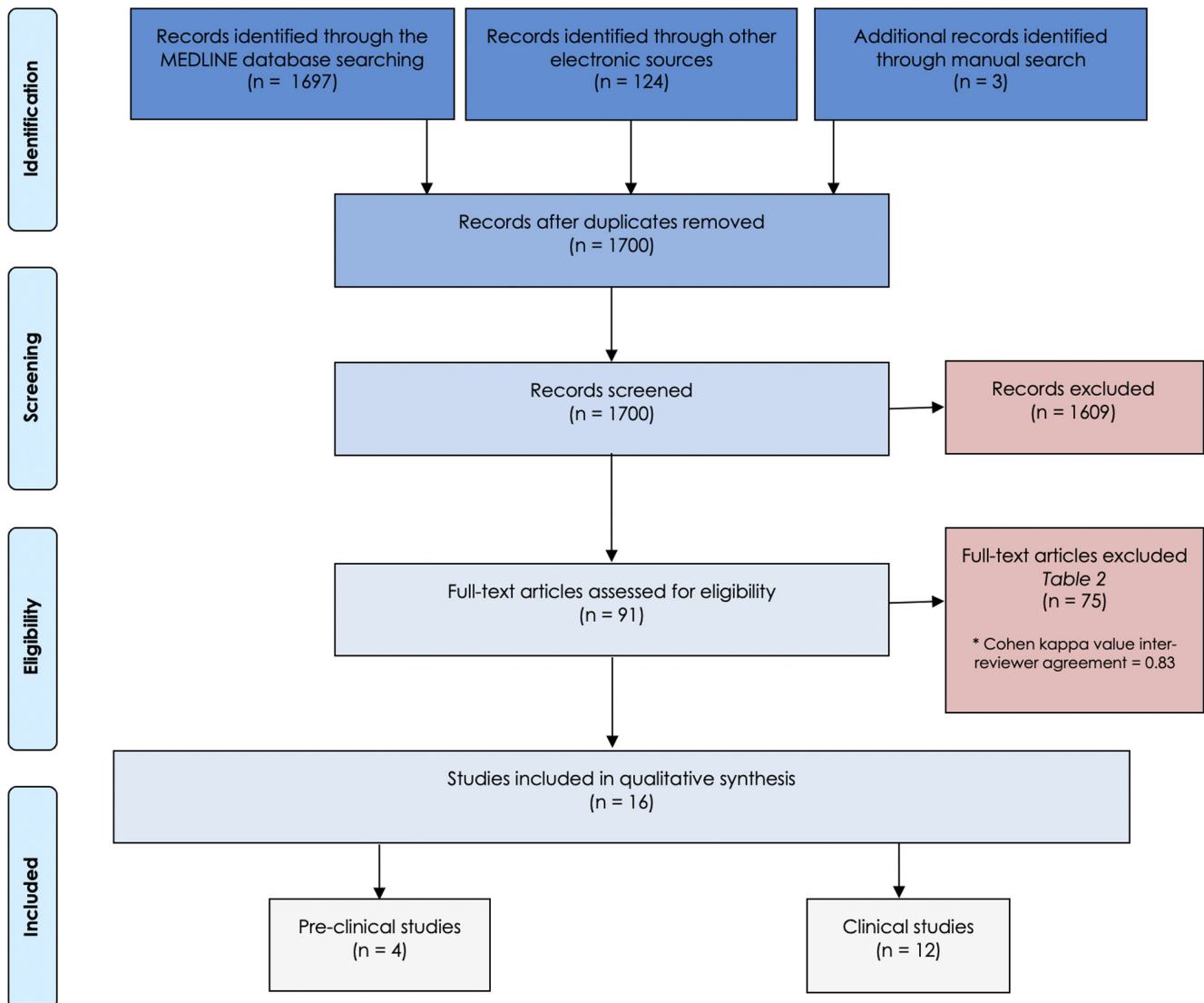


FIGURE 1 Flowchart of the systematic review

insertion torque recorded during implant placement. One study (Nohra et al., 2018) explored the effect of implant torque and BBT on bone remodeling. Li Manni et al. (2020) evaluated two different implant macro-designs. All the articles except one provided the BBT as baseline parameter. Covani et al. (2004) reported the baseline BLD. One PC study (Temmerman et al., 2015) grafted only when dehiscence or fenestrations were noted. Caliper, periodontal probe, and cone beam computed tomography (CBCT) were the methods used to assess the alveolar bone dimension at baseline. Seven studies assessed the radiographic outcome (Barone et al., 2015; Cardaropoli et al., 2006; Jung et al., 2017; Li Manni et al., 2020; Marconcini et al., 2018; Nohra et al., 2018; Temmerman et al., 2015)—5 of them reporting by means of periapical radiographs (Barone et al., 2016; Cardaropoli et al., 2006; Jung et al., 2017; Marconcini et al., 2018; Temmerman et al., 2015) and two using CBCT (Li Manni et al., 2020; Nohra et al., 2018). Furthermore, five studies reported clinical outcomes at latest follow-up assessment (Barone et al., 2015; Farronato et al., 2020; Jung et al., 2017; Marconcini et al., 2018; Schwarz et al., 2012).

The length of study periods ranged from 4 to 72 months. Only one study described patient-reported outcomes (PROMs; Li Manni et al., 2020).

3.1.2 | Preclinical studies

The preclinical model testing the influence of the BBT on the fate of the peri-implant hard and soft tissues was the canine model in all the studies included (Table 4). Overall, 152 sites (implants) were included and evaluated. Spontaneous healing was the most reported intervention (Baffone et al., 2015; Bengazi et al., 2014; Monje et al., 2019; Vignoletti et al., 2019), while one study further assessed experimental peri-implantitis using a ligature-induced model (Monje et al., 2019). Baffone et al. (2015) evaluated the influence of ridge width and abutment width upon the alveolar dimensional changes. Bengazi et al. (2014) analyzed the influence of the anatomical site (molar/premolar) and the presence/absence of peri-implant keratinized mucosa upon the alveolar changes. Monje et al. (2019) in turn evaluated the influence of BBT (≥ 1.5 mm vs.

TABLE 2 Excluded articles and reasons for exclusion.

Reason for exclusion	Reference
Simultaneous grafting procedure with no control group	Fenner et al. (2009), Fienitz et al. (2012) Hur et al. (2017), Moses et al. (2005), Nemcovsky and Artzi (2002), Qahash et al. (2008)
Early placement protocol with simultaneous bone regeneration	Nir-Hadar et al. (1998), Rodriguez-Ortiz et al. (2021)
Grafted sockets with no baseline dimension	Crespi et al. (2021), Duong et al. (2020)
Immediate implant placement protocol	Barone et al. (2015), Chen et al. (2007), Novaes Jr. et al. (2012), Penarrocha-Oltra et al. (2012), Suaid et al. (2014)
Implant stability quotient with no dimensional data	Bozkaya et al. (2021)
No baseline dimensional data/missing information	Abrahamsson et al. (2004, 1999, 1996, 2014), Baffone et al. (2012, 2011), Becker et al. (2007, 2017), Bratu et al. (2009), Carcuac et al. (2020), Carmagnola et al. (1999), Carmo Filho et al. (2019), Cesaretti et al. (2015), Chacun et al. (2021), Checchi et al. (2017), Cooper et al. (2007, 2015), Di Raimondo et al. (2021), Finelle et al. (2015), Gehrke et al. (2018), Jemt and Lekholm (2003, 2005), Jonker et al. (2020), Kim et al. (2016), Koutouzis et al. (2013), Lee et al. (2016, 2019), Noelken et al. (2014), Nowzari et al. (2006), Oeschger et al. (2020), Palombo et al. (2021), Patil et al. (2020), Raes et al. (2018), Sanz-Martin et al. (2017), Schropp et al. (2015), Schwarz et al. (2007, 2016), Souza et al. (2018), Thoma et al. (2019), van Eekeren et al. (2017), Vera et al. (2012), Yi et al. (2017)
Implant removal procedures	Pons et al. (2021)
Survey analysis	Fiorellini et al. (2020)
Only descriptive data on dimensional features	Glibert et al. (2018)
Retracted article	Calvo-Guirado et al. (2016)
Ridge expansion procedures	Beolchini et al. (2015), Scipioni et al. (1997)
Outside scope	da Silva Pereira et al. (2000), Deporter et al. (1988), Dursun et al. (2012), Lin et al. (2009), Onem et al. (2012), Sarmant and Meraw (2008), Schliephake et al. (2003), Tal et al. (2001), Wadamoto et al. (1996)
Case report	Yoda et al. (2017)
Only cortical thickness provided	Tanaka et al. (2018)

<1.5 mm) upon VBL of the BBW. Vignoletti et al. (2019) analyzed spontaneous healing in two early stages (2 and 8 weeks of follow-up). Two studies (Baffone et al., 2015; Bengazi et al., 2014) used calipers to measure the alveolar dimension at baseline, one study (Monje et al., 2019) used a tracking system, and another study (Vignoletti et al., 2019) used a periodontal probe. All the studies performed histological analysis at latest follow-up. Spontaneous healing was assessed over a range of 2–12 weeks, though an arm of one study (Monje et al., 2019) evaluated the dimensional changes in an experimentally induced peri-implantitis model at 5 months follow-up.

3.2 | Influence of baseline BLD upon BLD changes

3.2.1 | Clinical studies

Only two studies (Covani et al., 2004; Temmerman et al., 2015) reported on the baseline alveolar bone dimension, and only one of them documented the alveolar bone changes. Covani et al. (2004) demonstrated that after an average of 4 months after implant placement, the BLD was reduced by about 3 mm. None of the studies reported on the BBT changes.

3.2.2 | Preclinical studies

Only one study assessed the BLD changes at baseline. Baffone et al. (2015) showed that the narrower the baseline BLD, the thinner the BBW after 3 months of follow-up. Thus, implants installed in regular-sized alveolar ridges exhibited greater horizontal bone loss when compared to implants installed in narrower ridges. However, lesser vertical buccal bony crestal resorption was recorded compared to implants installed in reduced alveolar ridges.

3.3 | Influence of baseline BLD upon clinical and radiographic outcomes

3.3.1 | Clinical studies

No clinical study reported on the integrity of the BBW or the BBT using three-dimensional radiographic techniques. Only one study examined the radiographic findings (Temmerman et al., 2015), documenting a mean radiographic peri-implant marginal bone loss of approximately 0.8 mm (mean from mesial and distal linear measurements) at 3 years of follow-up with implants placed in narrow alveolar crests (4.5 mm).

3.3.2 | Preclinical studies

None of the preclinical studies reported on the clinical or radiographic outcomes.

3.4 | Influence of baseline BLD upon biological complications

3.4.1 | Clinical studies

None of the clinical studies reported on BLD and its association with biological complications.

3.4.2 | Preclinical studies

None of the preclinical studies reported on the occurrence of biological complications.

3.5 | Influence of baseline BLD upon PROMs

No clinical study assessed the association between BLD and PROMs.

3.6 | Influence of BBT upon buccal bone changes

3.6.1 | Clinical studies

All the included studies except one (Covani et al., 2004) reported on baseline BBT. Mean BBW ranged from 0 mm (Jung et al., 2017; Schwarz et al., 2012; dehiscence-like defect) to 1.84 mm (Spray et al., 2000). Few studies presented ranges instead of mean values (Barone et al., 2016; Farronato et al., 2020; Marconcini et al., 2018; Nohra et al., 2018; Temmerman et al., 2015). Overall, seven studies provided data referring to VBL or BBT at re-assessment (Cardaropoli et al., 2006; Jung et al., 2017; Li Manni et al., 2020; Nohra et al., 2018; Oda et al., 2021; Schwarz et al., 2012; Spray et al., 2000). Dimensional changes were noted in BBW ranging from approximately 0.3 mm to approximately 1.75 mm. Spray et al. (2000) in a large sample size study, showed that whenever ≥ 1.8 mm of BBW was present during implant placement, no VBL occurred (which demonstrates the integrity of the BBW), while in thinner BBW (<1.8 mm) assessed in the implant placement stage, a rising tendency was evidenced toward greater VBL values. Nohra et al. (2018) showed that implants presenting BBT <2 mm at baseline exhibited 8x greater VBL (2.34 mm vs. 0.31 mm) when compared to implants displaying BBT ≥ 2 mm. One study (Jung et al., 2017) further demonstrated progressive VBL of 0.17 mm when a dehiscence-like defect of 3.2 mm was left for spontaneous non-assisted healing.

3.6.2 | Preclinical studies

Two studies (Bengazi et al., 2014; Vignoletti et al., 2019) reported on the mean baseline BBT, while one study (Monje et al., 2019) clustered this variable into ranges. Mean BBT ranged from

TABLE 3 Clinical studies included in the qualitative analysis.

Author (year)	Study design	Experimental group	Sample size (implants)	Buccal bone wall thickness in implant placement stage (mm)	Alveolar bucco-lingual dimension (mm)	Vertical bone defect (mm)	Buccal bone wall thickness at re-assessment (mm)	Alveolar bucco-lingual dimension at re-assessment (mm)	Vertical bone loss (mm)	Method of assessment	
Barone et al. (2016)	RCT	Spontaneous healing after implant placement with bone with high (50–100 Ncm) insertion torque (50 Ncm)	58	<1	NR	NR	NR	NR	NR	NR	
				≥1	NR	NR	NR	NR	NR	NR	
		Spontaneous healing after implant placement with regular insertion torque (50 Ncm)	58	<1	NR	NR	NR	NR	NR	NR	NR
				≥1	NR	NR	NR	NR	NR	NR	NR
Cardaropoli et al. (2006)	PC	Spontaneous healing	11	1.2 (1)	NR	NR	0.8 (0.3)	NR	NR	Caliper	
Covani et al. (2004)	PC	Spontaneous healing	15	NR	8.8 (2.3)	NR	NR	5.8 (1.3)	NR	Probe	
Farronato et al. (2020)	PC	Spontaneous healing	23	<0.5	NR	NR	NR	NR	NR	Caliper	
			29	>0.5 <1.5	NR	NR	NR	NR	NR	NR	
			26	≥1.5	NR	NR	NR	NR	NR	NR	
Jung et al. (2017)	RCT	Spontaneous healing (<5 mm in height dehiscence defect)	12	0	NR	3.2 (1.1)	NR	NR	0.17 (1.7)	Probe	
		Simultaneous guided bone regeneration (<5 mm in height dehiscence defect)	10	0	NR	3.6 (1.3)	NR	NR	(+) 1.7 (2.2)		
Li Manni et al. (2020)	RTC	Spontaneous healing with circular-neck implant	17	1.34 (1.08)	NR	NR	1.03 (1.05)	NR	NR	CBCT	
		Spontaneous healing with triangular-neck implant	17	1.34 (0.74)	NR	NR	1.08 (0.72)	NR	NR		
Marconcini et al. (2018)	RCT	Spontaneous healing after implant placement with bone with high (50–100 Ncm) insertion torque (50 Ncm)	58	<1	NR	NR	NR	NR	NR	NR	
				≥1	NR	NR	NR	NR	NR	NR	
		Spontaneous healing after implant placement with regular insertion torque (50 Ncm)	58	<1	NR	NR	NR	NR	NR	NR	
				≥1	NR	NR	NR	NR	NR		
Nohra et al. (2018)	PC	Spontaneous healing with 3 different ranges of insertion torque	18	<2	NR	NR	NR	NR	2.34 (2.16)	Caliper	
		Spontaneous healing with 3 different ranges of insertion torque	21	≥2	NR	NR	NR	NR	0.31 (0.63)		

Time of re-assessment (months)	Length of study period (months)	Clinical outcome					Radiographic outcome		Take home message
		Probing pocket depth (mm)	Bleeding on probing (%)	Mucosal recession (mm)	Suppuration (%)	Clinical attachment level (mm)	Method of assessment	Marginal bone level (mm)	
NR	12	NR	NR	1.07	NR	NR	Periapical radiograph	0.71 (0.39)	Sites with a thick buccal bone wall (≥1 mm) are less prone to buccal soft tissue recession than sites with a thin buccal bone wall
		NR	NR	0.78	NR	NR			
		NR	NR	0.35	NR	NR		1.11 (0.39)	
		NR	NR	0.15	NR	NR		(12m)	
6	12	NR	NR	NR	NR	NR	Periapical radiograph	1.9 (1.1)	Following implant placement in the healed alveolar ridge, remodeling of bone takes place, which is manifested in diminished dimensions, both horizontally and vertically, at the facial aspect of the implant
4	4	NR	NR	NR	NR	NR	NR	NR	Implants placed in healed ridges undergo dimensional changes due to bone resorption
NR	36	NR	NR	1.22	NR	NR	NR	NR	The buccal bone thickness at the time of implant placement may potentially affect buccal mucosal margin stability
		NR	NR	0.64	NR	NR	NR	NR	
		NR	NR	(+) 0.77	NR	NR	NR	NR	
6	18	2.9 (0.9)	0.07 (0.1)*	3.3	NR	NR	Periapical radiograph	0.3 (0.4)	Sites that are left for spontaneous healing reveal more vertical bone loss at the buccal aspect within the early stages of healing and less bone stability during follow-up
		2.6 (1.0)	0.07 (0.1)*	3.07	NR	NR		(+) 0.02 (0.4)	
12	12	NR	NR	NR	NR	NR	CBCT	0.42 (0.67)	Minimal dimensional changes are expected when a minimal buccal bone thickness is present in the posterior maxilla
		NR	NR	NR	NR	NR		0.22 (0.30)	
NR	36	NR	NR	1.53	NR	NR	Periapical radiograph	1.03 (0.12)	Sites with a thick buccal bone wall (≥ 1 mm) are less prone to buccal soft tissue recession than sites with thick buccal bone wall
		NR	NR	0.82	NR	NR			
		NR	NR	0.57	NR	NR		1.53 (0.29)	
		NR	NR	0.11	NR	NR			
12	12	NR	NR	NR	NR	NR	CBCT	0.36 (0.34)	Insertion torque and mucosal tissue thickness do not influence implant survival or marginal bone loss. Buccal bone thickness of ≥2mm was associated with a minimal marginal bone remodeling
		NR	NR	NR	NR	NR		0.03 (0.42)	

TABLE 3 (Continued)

Author (year)	Study design	Experimental group	Sample size (implants)	Buccal bone wall thickness in implant placement stage (mm)	Alveolar bucco-lingual dimension (mm)	Vertical bone defect (mm)	Buccal bone wall thickness at re-assessment (mm)	Alveolar bucco-lingual dimension at re-assessment (mm)	Vertical bone loss (mm)	Method of assessment
Oda et al. (2021)	RC	Spontaneous healing	17	1.43	NR	NR	0.8	NR	NR	CBCT
Schwarz et al. (2012)	PC	Simultaneous guided bone regeneration	8	0	NR	0	NR	NR	NR	Caliper
			8	0	NR	1	0	NR	NR	
			8	0	NR	3.6 (1.5)	0	NR	NR	
Spray et al. (2000)	PC	Spontaneous healing	140	1.26 (0.87)	NR	>3	0.7 (1.70)*	NR	NR	Caliper and probe
			189	1.54 (1.11)	NR	2.1–3		NR	NR	
			415	1.67 (1.10)	NR	1.1–2		NR	NR	
			733	1.75 (1.41)	NR	0.1–1		NR	NR	
			716	1.83 (1.10)	NR	0		NR	NR	
			474	1.84 (1.41)	NR	0		NR	NR	
Temmerman et al. (2015)	PC	Spontaneous healing for buccal plates <1mm and simultaneous guided bone regeneration when dehiscence/ fenestration of implants placed 2mm subcrestal	98	<1	<4.5	NR	NR	NR	NR	NR

Abbreviations: CBCT, cone beam computed tomography; NR, not reported; PC, prospective cohort; RC, retrospective cohort; RCT, randomized controlled trial.

*Refers to mean value of the modified sulcular bleeding index.

0.9 mm (Bengazi et al., 2014) to 2.29 mm (Vignoletti et al., 2019). All the included studies documented VBL at re-assessment, while two studies (Bengazi et al., 2014; Vignoletti et al., 2019) reported BBT at re-assessment (range from approximately 0.1 to 1.3 mm). Data from three studies (Bengazi et al., 2014; Monje et al., 2019; Vignoletti et al., 2019) demonstrated that VBL occurs regardless of the baseline BBT over a range of approximately 0.3–4 mm. Data from one study (Monje et al., 2019) showed that on average, a baseline BBW <1.5 mm is exposed to approximately 4 mm of VBL under spontaneous healing, while in scenarios where BBW is ≥ 1.5 mm, VBL is limited to about 0.1 mm. This tendency was sustained in experimentally induced peri-implantitis, showing a difference of approximately 0.9 mm in favor of BBW ≥ 1.5 mm. One study (Baffone et al., 2015) that did not report baseline BBT, found that narrower alveolar ridges tended to have thinner BBW at re-entry.

3.7 | Influence of baseline BBT upon clinical and radiographic outcomes

3.7.1 | Clinical studies

Overall, five studies (Barone et al., 2016; Farronato et al., 2020; Jung et al., 2017; Marconcini et al., 2018; Schwarz et al., 2012) reported on

the clinical parameters, with mucosal recession (MR) being the most frequently documented parameter. No notable differences were observed in probing pocket depth (PPD) according to baseline BBT or to baseline vertical bone defect in dehiscence-type defects. In contrast, bleeding on probing was seen to increase in deeper vertical bone defects in dehiscence-type defects. Mucosal recession (MR) was significantly increased in the presence of thinner BBT or deeper vertical bone defects in dehiscence-type defects. In turn, seven studies (Barone et al., 2016; Cardaropoli et al., 2006; Jung et al., 2017; Li Manni et al., 2020; Marconcini et al., 2018; Nohra et al., 2018; Temmerman et al., 2015) further reported on marginal bone level (MBL) using radiographic analyses. The MBL values ranged from 0.2 to 1.9 mm under spontaneous healing. No comparisons could be made, due to the heterogeneity of the groups. Interestingly, Nohra et al. (2018) showed that implants presenting BBT <2 mm at baseline exhibited 10 \times greater MBL (0.36 mm vs. 0.03 mm), respectively, when compared to implants displaying BBT ≥ 2 mm.

3.7.2 | Preclinical studies

Only one study (Monje et al., 2019) examined the clinical and radiographic parameters in experimental ligature-induced peri-implantitis. Greater PPD, MR, sulcular bleeding index (mSBI), and

Time of re-assessment (months)	Length of study period (months)	Clinical outcome				Radiographic outcome			Take home message
		Probing pocket depth (mm)	Bleeding on probing (%)	Mucosal recession (mm)	Suppuration (%)	Clinical attachment level (mm)	Method of assessment	Marginal bone level (mm)	
72	72	NR	NR	NR	NR	NR	NR	NR	Significant buccal bone loss occurs over the long-term in the edentulous maxilla
4	48	2.9 (0.7)	29.1 (21.3)	0.2 (0.3)	NR	3.1 (0.8)	NR	NR	Implants exhibiting residual defect height values >1 mm are at a greater risk of developing peri-implant disease and are associated to an increase in mucosal recession
		2.8 (0.7)	45.8 (30.5)	0.5 (0.7)	NR	3.3 (0.8)			
		2.7 (0.8)	54.1 (24.8)	0.4 (0.6)	NR	3.1 (1.2)			
Mandible (3–4)— Maxilla (3–8)	NR	NR	NR	NR	NR	NR	NR	NR	The greatest bone resorption occurs when the buccal plate at implant placement is <1.4 mm. Bone loss decreases with <1.7 mm baseline buccal plates. If bone is ≥1.8, changes are inexistent.
		NR	NR	NR	NR	NR	NR	NR	
		NR	NR	NR	NR	NR	NR	NR	
		NR	NR	NR	NR	NR	NR	NR	
		NR	NR	NR	NR	NR	NR	NR	
3.6	NR	NR	NR	NR	NR	Periapical radiograph	0.79	At sites with limited buccolingual dimensions (≤ 4.5 mm), implants can be successful if placed subcrestal	

suppuration were noted under a baseline BBW < 1.5 mm when compared to BBW ≥ 1.5 mm. Mean bone loss was approximately 5 mm in both groups.

3.8 | Influence of baseline BBT upon biological complications

3.8.1 | Clinical studies

None of the clinical studies reported on BBT and its association with biological complications.

3.8.2 | Preclinical studies

One study (Monje et al., 2019) examined the progression of peri-implantitis in an experimental model. In general terms, a more acute inflammatory condition together with MR was noted in BBW < 1.5 mm.

3.9 | Influence of baseline BBT upon PROMs

A single study (Li Manni et al., 2020) noted no difference in PROMs according to the type of implant or the baseline BBT.

3.10 | Influence of bone regeneration on the buccal bone changes

3.10.1 | Clinical studies

One study (Jung et al., 2017) showed that VBL was significantly increased at 6 months of follow-up under conditions of spontaneous healing when compared to simultaneous bone regeneration.

3.10.2 | Preclinical studies

No preclinical study evaluated the impact of bone regeneration upon buccal bone changes.

TABLE 4 Preclinical studies included in the qualitative analysis.

Author (year)	Experimental model	Experimental design	Sample (implants)	Experimental group	Method of assessment	Buccal bone wall thickness in implant placement stage (mm)	Bucco-lingual alveolar bone dimension at implant placement (mm)	Buccal bone thickness at re-assessment (mm)	Bucco-lingual alveolar bone dimension at re-assessment (mm)
Baffone et al. (2015)	Labrador dog	Spontaneous healing	6	Narrow ridge—Narrow abutment (3.3 mm)	Caliper	NR	4.1 (0.6)	1 (0.7)	NR
			6	Wide ridge—Wide abutment (4.6 mm)		NR	5.4 (1.3)	1 (0.5)	NR
			6	Narrow ridge—Wide abutment (3.3 mm)		NR	3.7 (0.6)	0.7 (0.4)	NR
			6	Wide ridge—Narrow abutment (4.6 mm)		NR	6.2 (1.2)	1.5 (0.7)	NR
Bengazi et al. (2014)	Beagle dog	Spontaneous healing	6	Premolar—Alveolar mucosa	Caliper	0.9 (0.0)	NR	0.7 (0.3)	NR
			6	Premolar—Masticatory mucosa		0.9 (0.0)	NR	0.4 (0.6)	NR
			6	Molar- Alveolar mucosa		2.3 (0.3)	NR	2.2 (0.5)	NR
			6	Molar- Masticatory mucosa		2.4 (0.1)	NR	1.5 (0.8)	NR
Monje et al. (2019)	Beagle dog	Spontaneous healing	18	Thin buccal bone	Tracking system	<1.5	NR	NR	NR
			18	Thick buccal bone		≥1.5	NR	NR	NR
		Experimental peri-implantitis	18	Thin buccal bone		<1.5	NR	NR	NR
			18	Thick buccal bone		≥1.5	NR	NR	NR
Vignoletti et al. (2019)	Beagle dogs	Spontaneous healing	16	2-week healing	Probe	2.29 (0.15)	NR	1.96 (0.9)	NR
			16	8-week healing		2.29 (0.15)	NR	0.94 (0.79)	NR

3.11 | Influence of bone regeneration on the clinical and radiographic outcomes

3.11.1 | Clinical studies

A single study (Jung et al., 2017) demonstrated greater PPD (approximately 0.3 mm), MR (approximately 0.3 mm), and MBL (approximately 0.3 mm) when spontaneous healing was applied in dehiscence-type defects compared to augmented sites.

3.11.2 | Preclinical studies

No preclinical study explored the impact of bone regeneration on the clinical and radiographic outcomes of augmented sites.

3.12 | Influence of bone regeneration upon biological complications

3.12.1 | Clinical studies

One study (Schwarz et al., 2012) showed that the larger the dehiscence-type defect after regeneration, the greater the risk of biological complications (i.e., peri-implant mucositis) at four years of follow-up.

3.12.2 | Preclinical studies

No preclinical study explored the impact of bone regeneration on the occurrence of biological complications.

Vertical bone loss (mm)	Time of re-assessment (months)	Clinical outcome				Radiographic outcome			Take home message
		Probing pocket depth (mm)	Modified sulcular bleeding index (mean)	Mucosal recession (mm)	Suppuration (%)	Clinical attachment level (mm)	Method of assessment	Marginal bone level (mm)	
1.7 (1.7)	3	NR	NR	NR	NR	NR	NR	NR	Implants installed in regular- sized alveolar ridges have greater horizontal, but lesser vertical buccal bony crestal resorption compared to implants installed in reduced alveolar ridges.
1.3 (0.9)		NR	NR	NR	NR	NR	NR	NR	
0.9 (0.3)		NR	NR	NR	NR	NR	NR	NR	
1.5 (0.5)		NR	NR	NR	NR	NR	NR	NR	
1.7 (0.6)	3	NR	NR	NR	NR	NR	NR	NR	Greater buccal bony crest resorption and a more apical soft tissue marginal position should be expected when implants are surrounded with thin alveolar mucosa at the time of placement, independently of the thickness of the buccal bony crest
0.9 (0.6)		NR	NR	NR	NR	NR	NR	NR	
2.3 (0.9)		NR	NR	NR	NR	NR	NR	NR	
1.4 (0.5)		NR	NR	NR	NR	NR	NR	NR	
4.07	2	NR	NR	NR	NR	NR	NR	NR	Lower bone levels are expected when the critical buccal bone thickness is <1.5 mm. Experimental peri-implantitis is, in part, attributable to the greater vertical resorption of the buccal plate during initial remodeling. Clinical parameters are greater for implants placed in ridges under the critical buccal bone thickness when compared to implants placed ≥1.5 mm of buccal bone thickness
0.11		NR	NR	NR	NR	NR	NR	NR	
3.69	5	3.6	1.31	0.14	17	NR	CT	5.02	
2.83		3.21	1.1	(+)0.08	3	NR			
0.29 (0.18)	<1	NR	NR	NR	NR	NR	NR	NR	
0.59 (0.58)	2	NR	NR	NR	NR	NR	NR	NR	Pronounced buccolingual ridge alterations and vertical bone loss are noted at 2 and 8 weeks after implant placement in healed ridges

3.13 | Risk of bias

Risk of bias for clinical and preclinical studies are presented in [Tables S1–S3](#). In summary, the 4 RCTs, evaluated with the risk-of-bias 2.0. tool, were scored at “some concerns” of bias. When considering the additional eight clinical non-RCTs, based on the COHORT version of the Newcastle-Ottawa Scale, five studies were graded at “high risk” of bias (3–6 stars), and five studies (eight stars) were scored at “low risk” of bias. Finally, with respect to the four animal studies included, two of them were scored “low” and 2 “unclear” risk of bias.

4 | DISCUSSION

4.1 | Main findings

Given the frequency of biological and esthetic complications in implant dentistry associated to buccal bone resorption, the question to be addressed is: What is the minimum BBT required to secure favorable outcomes conditioned to the dimensional changes after implant placement? The present systematic review yielded the following findings: (1) the clinical evidence demonstrated that during healing, dimensional changes occur in the alveolar bone and

in the BBW that may compromise the integrity of the peri-implant bone, leading to VBL and MR, particularly in scenarios exhibiting a thin BBW; (2) the preclinical evidence validated the fact that implants placed in the presence of a thin BBW are more prone to exhibit major dimensional changes; (3) clinical data indicated that in scenarios where dehiscence-type defects are left to heal spontaneously, greater VBL and MR together with the occurrence of biological and esthetic complications are to be expected; (4) in a ligature-induced peri-implantitis model, scenarios involving a thin BBW (BBT < 1.5 mm) at baseline were characterized by progression of the disease with more mucosal inflammation, MR and VBL when compared to a thick BBW (BBT ≥ 1.5 mm); and (5) the augmentation of dehiscence-type defects is associated to hard and soft tissue stability. However, the present systematic review (6) failed to identify a specific threshold for guaranteeing residual alveolar bone in the

buccal wall after implant placement. Nonetheless, (7) it seems that preclinical and clinical evidence points towards BBT < 1.5–2 mm tended to show greater VBL, MR, and BBT reduction (Figure 2).

4.2 | Findings from clinical studies

Clinical data demonstrated changes in BBW after implant placement in healed ridges over a range of approximately 0.3–1.75 mm during up to 72 months of follow-up, with changes in the BLD of approximately 3 mm at 6 months of follow-up. Moreover, it was shown that completely intact BBW was guaranteed in scenarios that presented ≥ 1.8 mm at implant placement (Spray et al., 2000). On the other hand, scenarios characterized by approximately 1.2 mm during initial examination displayed > 3 mm of VBL (Spray et al., 2000). Nohra et al., 2018

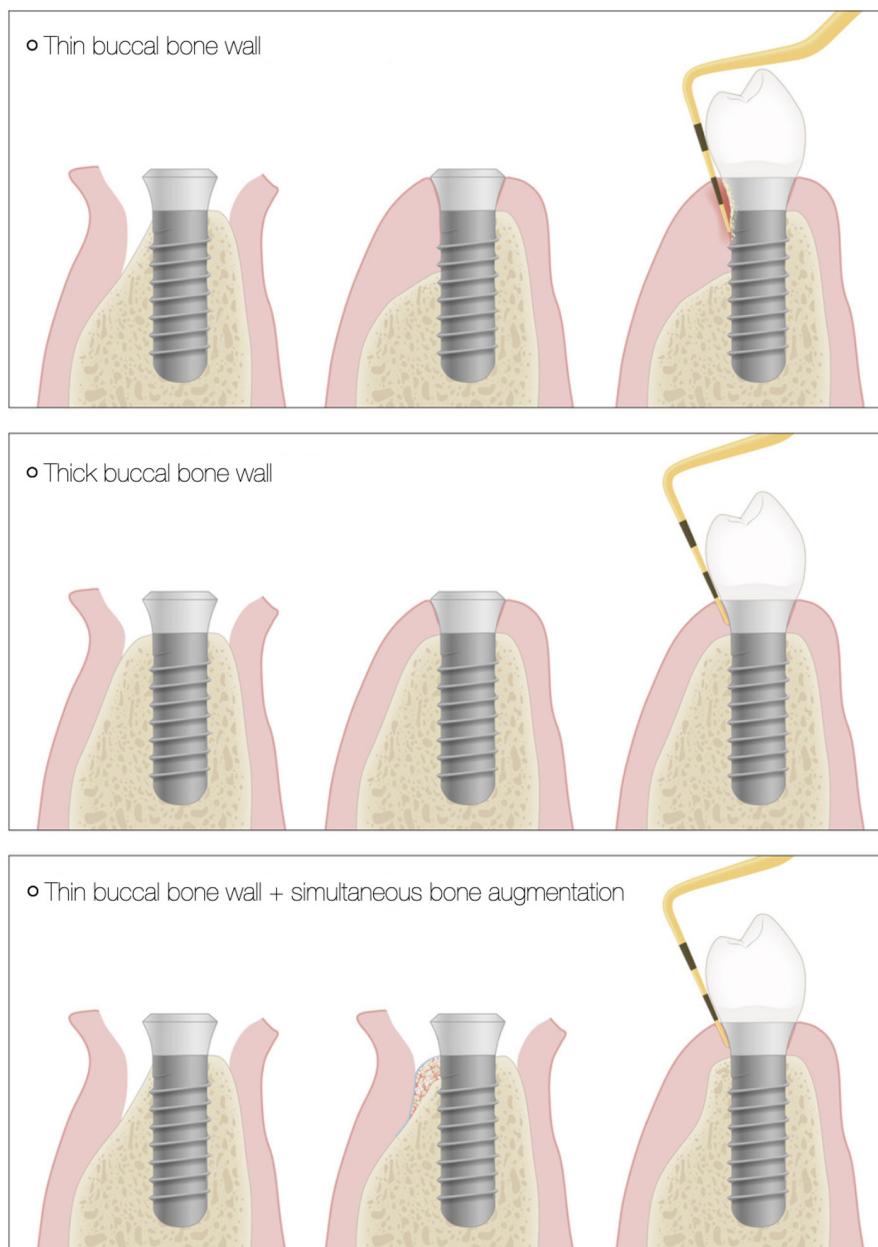


FIGURE 2 Schematic representation of avascular necrosis of the buccal bony wall according to the baseline BBT and the potential of bone augmentation to compensate scenarios characterized by a thin BBT.

showed that implants presenting $BBT < 2\text{ mm}$ at baseline exhibited $8\times$ and $10\times$ greater VBL (2.34 mm vs. 0.31 mm) and MBL (0.36 mm vs. 0.03 mm), respectively, when compared to implants displaying $BBT \geq 2\text{ mm}$. It is remarkable, however, that in subcrestal implants placed in reduced BLD ($< 4.5\text{ mm}$), implant therapy can yield solid outcomes with minimal peri-implant bone loss as determined by periapical radiographs (Temmerman et al., 2015). Nonetheless, it should be noted that this study did not evaluate VBL at the buccal aspect during re-examination or assess the clinical parameters during the study period. Moreover, early dimensional changes yielded minimal changes in the posterior maxilla (Li Manni et al., 2020). In fact, confounders other than BBT could further impact upon the dimensional changes. For instance, the shape of the edentulous ridge dictates that the more apical the BLD is examined in a cross-sectional view, the wider it is when compared to the most coronal location since it follows a divergent morphology (Chen et al., 2021). This strategy may assist in compensating for the thin BBW at the most coronal aspect of the ridge. In turn, the anatomical area also may play a relevant role. The mandibular process is predominantly composed of cortical bone, which is poorly vascularized, while the maxillary bone is more cancellous and richer in blood supply. In fact, the thickness of the cortical layer at the coronal aspect of the mandibular ridge is approximately 1.4 mm (Chatvarathana et al., 2017), versus approximately 2 mm at 3 mm below the crest in the molar area (Katranji et al., 2007)—being significantly thinner in the edentulous maxilla (Katranji et al., 2007). Moreover, Lindhe et al. (2013) showed that the cortical crest was wider in the mandible than in the maxilla, and widest in the symphysis region of the mandible. Further, it was demonstrated that the proportion of bone marrow was greater in the maxilla than in the mandible. Hence, it is hypothesized that the thickness of the cortical bone may dictate the extent of the remodeling process, being more critical in the mandibular anterior than in the posterior maxillary ridges.

Simultaneous augmentation was seen to mitigate dimensional changes, VBL, MR, and biological complications. One RCT (Jung et al., 2017) explored soft and hard tissue changes of dehiscence-type defects left for spontaneous healing and simultaneous horizontal bone augmentation using GBR. In fact, simultaneously grafted sites showed a significant gain in vertical bone, while nongrafted sites exhibited progressive VBL and greater MR. A four-year PC study (Schwarz et al., 2012) showed that successful lateral regeneration procedures during implant placement that secure complete buccal bone ($BBT = 0.8\text{ mm}$) are less prone to experience biological complications during the study period (4-year follow-up). Thus, data from these two studies highlight the role of simultaneous bone augmentation in scenarios characterized by a lack of buccal bone. The question of whether implants with thin BBW clinically benefit from regeneration was not addressed, however.

4.3 | Findings from preclinical studies

In light of measurement errors derived from radiographic methods (i.e., CBCT) to determine peri-implant bone dimensions, preclinical studies

were further considered. insight on the actual significance Preclinical data afforded insight into the influence of BBT upon the dimensional changes. It was seen that dimensional changes may compromise BLD and BBW in healed alveolar ridges after implant placement. A range from approximately $0.1\text{--}1.4\text{ mm}$ in BBT changes was noted. Vertical bone loss ranged from approximately $0.3\text{--}4\text{ mm}$. It is relevant to note that narrower alveolar ridges have a greater tendency to show a thin BBW at re-assessment (Baffone et al., 2015). Data from one study (Monje et al., 2019) showed that a baseline $BBT < 1.5\text{ mm}$ is exposed on average to about 4 mm of VBL under spontaneous healing, while in scenarios where $BBT \geq 1.5\text{ mm}$, VBL is limited to approximately 0.1 mm . This tendency was sustained in experimentally induced peri-implantitis, showing a difference of approximately 0.9 mm in favor of $BBT \geq 1.5\text{ mm}$. Moreover, two studies (Bengazi et al., 2014; Vignoletti et al., 2019) reported changes in BBT at re-assessment ranging from approximately 0.2 mm to approximately 1.5 mm . The abovementioned study (Monje et al., 2019) further provided information on the soft and hard tissues during experimental peri-implantitis. In general lines, a more acute inflammatory condition together with greater VBL and MR were noted in scenarios where the initial BBW was $< 1.5\text{ mm}$. Another confounder in relation to the influence of initial BBT upon dimensional changes was the nature of the alveolar mucosa (Bengazi et al., 2014). Greater VBL changes occurred when implants were surrounded by thin nonkeratinized mucosa at the time of implant placement, in contrast to keratinized mucosa. Therefore, based on preclinical data, it seems that dimensional changes occur as a consequence of implant placement and that major resorption that may compromise the integrity of bone along the buccal aspect of the implant may lead to more aggressive peri-implantitis.

4.4 | Understanding the biological mechanism behind these findings

This systematic review evidenced the dimensional changes that occur after implant placement in healed alveolar ridges. This may reflect an avascular necrosis phenomenon as a consequence of damage to the alveolar bone (Chang et al., 1993; Roux & Orcel, 2000). The alveolar process is composed of cortical bone at the outer aspect, whereas the central portion of the mandible is characterized by a more cancellous structure. The cortical bone receives its blood supply branched from the outside through blood vessels of the periosteum, and from the inside of the endosteum (Roush et al., 1989). Therefore, when an implant is inserted with an open-flap procedure, the blood supply from both sources is disrupted (Roux & Orcel, 2000). Avascular necrosis following implant placement is initiated 12 h after disruption of the blood supply when the hematopoietic cells that are particularly sensitive to low oxygen levels die. This event is followed by the death of bone cells such as osteocytes and osteoblasts, leading to more noticeable osteoclast activity (Mankin, 1992). In consequence, the blood supply might not be sufficient to repair the bone at the buccal aspect. In response, osteoclasts activated by the RANKL/RANK pathway and mediated by a transcription factor (nuclear factor of activated T cells) induce buccal bone resorption (Roux

& Orsel, 2000). VBL together with buccal MR are thus attributable to this process. These changes may have a detrimental impact upon the integrity of the buccal bone and mucosal stability, compromising the functional and esthetic outcomes.

4.5 | Clinical implications

Considering that the clinical and preclinical data indicated that scenarios with an initial thin BBW (BBT ≤ 1.5 mm) may experience major dimensional changes that can compromise the integrity of the buccal bone and/or the stability of the soft tissues, simultaneous bone augmentation is encouraged (Figure 2). This may gain further importance

in the mandibular bone (Figure 3) and in scenarios lacking keratinized mucosa. Other graftless clinical strategies to compensate BBW in narrower ridges include slightly submerging bone-level implants using transmucosal abutments. This concept is not applicable to tissue-level implants, owing to the increased depth of the mucosal tunnel that may lead to mucosal inflammation (Chan et al., 2019). The use of narrow-diameter implants (NDI) may be also a potential solution to approach situations of thin BBW. However, NDIs are mostly limited to premolar sites in both jaws and anterior implant sites in the mandible to achieve the desired emergence profile. For instance, the use of narrow-diameter bone-level implants in the posterior mandible may contribute to a convex emergence profile, which in turn may increase the risk of peri-implant biological complications (Katafuchi

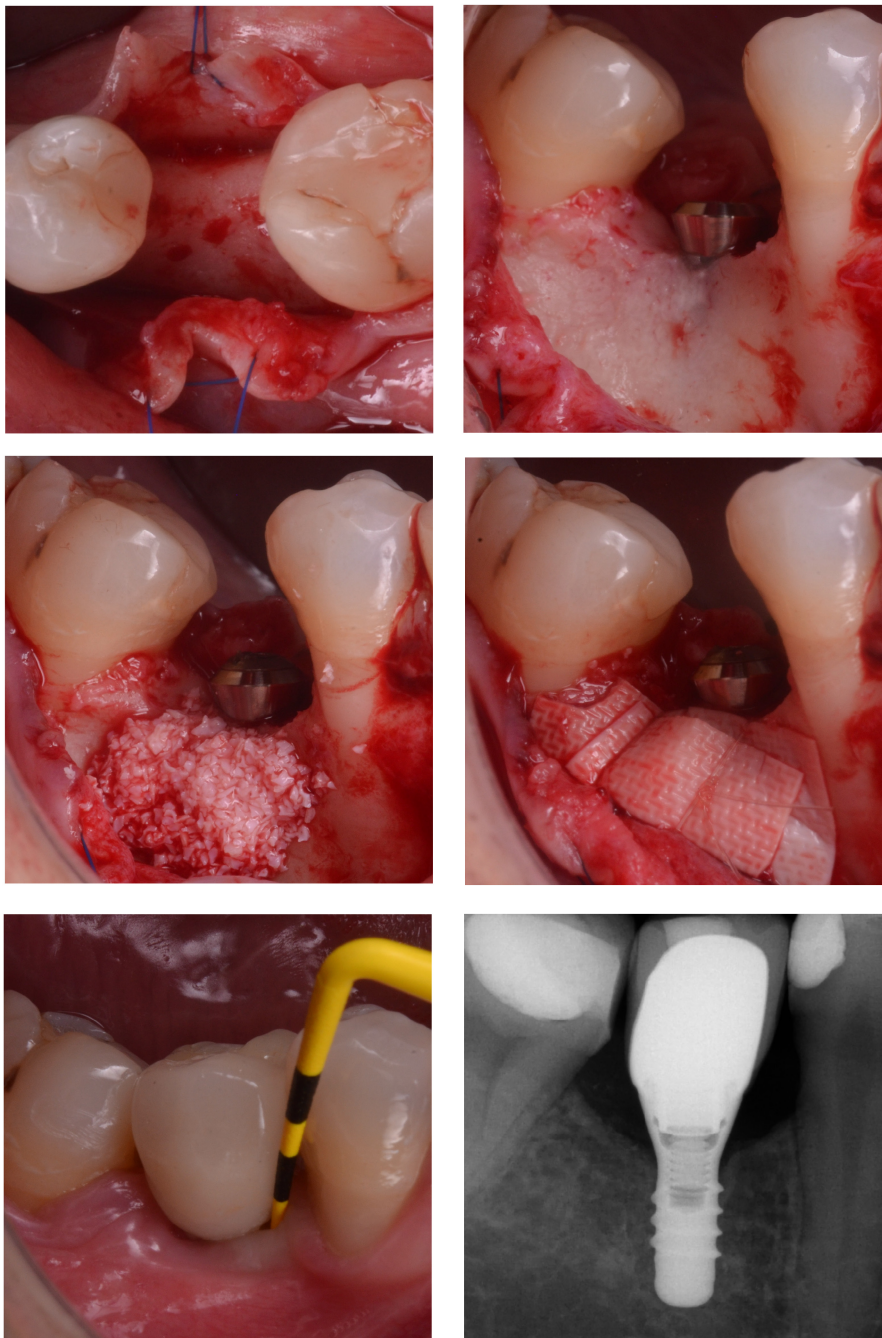


FIGURE 3 Case scenario of thin BBW in the posterior mandible; (a) occlusal view indicating the narrow alveolar dimension, (b) implant three-dimensional position must solely be dictated by the desired emergence profile, (c) grafting with autogenous bone and slowly reabsorbing bone in two layers, (d) cross-linked membrane is used to fulfill the principle of compartmentalization, (e) clinical outcomes show mucosal stability and peri-implant health, (f) bone levels remain stable during follow-up.

et al., 2018). Another option to reduce the risk of an exposed micro-rough surface to the peri-implant sulcus is the utilization of a so-called hybrid design (HD) implant (Tarnow, 1993). A HD implant has by definition a micro-rough surface in the endo-osseous portion for improved bone anchorage, and a machined surface in the neck/shoulder area for the trans- and supracrestal area to reduce the risk for biofilm colonization, and hence the development of biologic complications over time (Monje et al., 2021; Serrano et al., 2022). The essence and inspiration of all HD implants is the tissue-level implant by Straumann first utilized in 1986 (Sutter et al., 1988). Long-term studies seem to document the increased risk for peri-implantitis for non-HD implants, when the micro-rough is exposed to the supracrestal area (Derks et al., 2016; Windael et al., 2021). A 10-year study with 1482 implants showed an odds ratio for the development of peri-implantitis of more than 5 for implants that exceeded an early bone loss of more than 0.5 mm during the first year of function. The overall incidence of peri-implantitis was 11.8% on an implant level, on top of a failure rate of 5.26% (Windael et al., 2021). In contrast, a 10-year clinical with 511 tissue-level implants with an HD, the failure rate was at 1.2%, and the prevalence of peri-implantitis at 1.8% (Buser et al., 2012).

4.6 | Limitations and recommendations for future research

Due to the heterogeneity of the data (i.e., different methods of assessment and landmarks), no meta-analyses could be performed. Moreover, it must be highlighted that conclusions are mainly derived from preclinical and nonrandomized clinical trials. Therefore, cautiousness must be exercised when interpreting the findings. Based on deficiencies identified in this systematic review, there are several open questions, which should be addressed with appropriate preclinical and clinical studies. Most important, the details of postsurgical bone resorption induced by avascular necrosis should be further examined with preclinical studies using sequential histologic analysis during the first 8 weeks of healing. This would allow a better understanding of the biology behind this phenomenon including information on the sequence and involved cells. Then, it is also of interest to explore the differences between implant sites in the maxilla and in the mandible, since differences in density of the BBW might result in different threshold values between thin and thick. Moreover, studies are needed to assess the impact of bone augmentation in scenarios characterized by a thin BBW, in order to gain insight into the influence of bone augmentation upon long-term soft and hard tissue stability.

5 | CONCLUSIONS

Dimensional changes occur as result of implant placement in healed ridges that may lead to instability of the peri-implant hard and soft tissues. Sites presenting a thin BBW are more prone to exhibit major

changes that may compromise the integrity of the buccal bone and may lead to biologic and esthetic complications. Hence, simultaneous bone augmentation of dehiscence-type defects or sites exhibiting a thin BBW may attenuate the buccal hard and soft tissue collapse that may jeopardize the long-term success and stability.

ACKNOWLEDGMENT

The authors thank Simon S. Jensen (University of Copenhagen, Denmark) for his review and lead during the performance of the systematic review and manuscript preparation.

CONFLICT OF INTEREST

The authors have no direct financial interests in the products and instruments listed in the paper.

DATA AVAILABILITY STATEMENT

The authors confirm that the data supporting the findings of this study are available within the article [and/or] its supplementary materials.

ORCID

Alberto Monje  <https://orcid.org/0000-0001-8292-1927>

Andrea Rocuzzo  <https://orcid.org/0000-0002-8079-0860>

REFERENCES

- Abrahamsson, I., Berglundh, T., Linder, E., Lang, N. P., & Lindhe, J. (2004). Early bone formation adjacent to rough and turned endosseous implant surfaces. An experimental study in the dog. *Clinical Oral Implants Research*, 15(4), 381–392. <https://doi.org/10.1111/j.1600-0501.2004.01082.x>
- Abrahamsson, I., Berglundh, T., Moon, I. S., & Lindhe, J. (1999). Peri-implant tissues at submerged and non-submerged titanium implants. *Journal of Clinical Periodontology*, 26(9), 600–607. <https://doi.org/10.1034/j.1600-051x.1999.260907.x>
- Abrahamsson, I., Berglundh, T., Wennstrom, J., & Lindhe, J. (1996). The peri-implant hard and soft tissues at different implant systems. A comparative study in the dog. *Clinical Oral Implants Research*, 7(3), 212–219. <https://doi.org/10.1034/j.1600-0501.1996.070303.x>
- Abrahamsson, I., Welander, M., Linder, E., & Berglundh, T. (2014). Healing at implants placed in an alveolar ridge with a sloped configuration: An experimental study in dogs. *Clinical Implant Dentistry and Related Research*, 16(1), 62–69. <https://doi.org/10.1111/j.1708-8208.2012.00460.x>
- Baffone, G., Lang, N. P., Pantani, F., Favero, G., Ferri, M., & Botticelli, D. (2015). Hard and soft tissue changes around implants installed in regular-sized and reduced alveolar bony ridges. An experimental study in dogs. *Clinical Oral Implants Research*, 26(1), 96–101. <https://doi.org/10.1111/clr.12306>
- Baffone, G. M., Botticelli, D., Canullo, L., Scala, A., Beolchini, M., & Lang, N. P. (2012). Effect of mismatching abutments on implants with wider platforms – An experimental study in dogs. *Clinical Oral Implants Research*, 23(3), 334–339. <https://doi.org/10.1111/j.1600-0501.2011.02320.x>
- Baffone, G. M., Botticelli, D., Pantani, F., Cardoso, L. C., Schweikert, M. T., & Lang, N. P. (2011). Influence of various implant platform configurations on peri-implant tissue dimensions: An experimental study in dog. *Clinical Oral Implants Research*, 22(4), 438–444. <https://doi.org/10.1111/j.1600-0501.2010.02146.x>
- Barone, A., Alfonsi, F., Derchi, G., Tonelli, P., Toti, P., Marchionni, S., & Covani, U. (2016). The effect of insertion torque on the clinical

- outcome of single implants: A randomized clinical trial. *Clinical Implant Dentistry and Related Research*, 18(3), 588–600. <https://doi.org/10.1111/cid.12337>
- Barone, A., Toti, P., Quaranta, A., Derchi, G., & Covani, U. (2015). The clinical outcomes of immediate versus delayed restoration procedures on immediate implants: A comparative cohort study for single-tooth replacement. *Clinical Implant Dentistry and Related Research*, 17(6), 1114–1126. <https://doi.org/10.1111/cid.12225>
- Becker, J., Ferrari, D., Hertel, M., Kirsch, A., Schaer, A., & Schwarz, F. (2007). Influence of platform switching on crestal bone changes at non-submerged titanium implants: A histomorphometric study in dogs. *Journal of Clinical Periodontology*, 34(12), 1089–1096. <https://doi.org/10.1111/j.1600-051X.2007.01155.x>
- Becker, K., Klitzsch, I., Stauber, M., & Schwarz, F. (2017). Three-dimensional assessment of crestal bone levels at titanium implants with different abutment microstructures and insertion depths using micro-computed tomography. *Clinical Oral Implants Research*, 28(6), 671–676. <https://doi.org/10.1111/clr.12860>
- Bengazi, F., Botticelli, D., Favero, V., Perini, A., Urbizo Velez, J., & Lang, N. P. (2014). Influence of presence or absence of keratinized mucosa on the alveolar bony crest level as it relates to different buccal marginal bone thicknesses. An experimental study in dogs. *Clinical Oral Implants Research*, 25(9), 1065–1071. <https://doi.org/10.1111/clr.12233>
- Beolchini, M., Lang, N. P., Ricci, E., Bengazi, F., Triana, B. G., & Botticelli, D. (2015). Influence on alveolar resorption of the buccal bony plate width in the edentulous ridge expansion (E.R.E.) – An experimental study in the dog. *Clinical Oral Implants Research*, 26(1), 109–114. <https://doi.org/10.1111/clr.12308>
- Bozkaya, S., Uraz, A., Guler, B., Kahraman, S. A., & Turhan Bal, B. (2021). The stability of implants and microbiological effects following photobiomodulation therapy with one-stage placement: A randomized, controlled, single-blinded, and split-mouth clinical study. *Clinical Implant Dentistry and Related Research*, 23(3), 329–340. <https://doi.org/10.1111/cid.12999>
- Bratu, E. A., Tandlich, M., & Shapira, L. (2009). A rough surface implant neck with microthreads reduces the amount of marginal bone loss: A prospective clinical study. *Clinical Oral Implants Research*, 20(8), 827–832. <https://doi.org/10.1111/j.1600-0501.2009.01730.x>
- Buser, D., Janner, S. F., Wittneben, J. G., Bragger, U., Ramseier, C. A., & Salvi, G. E. (2012). 10-Year survival and success rates of 511 titanium implants with a sandblasted and acid-etched surface: A retrospective study in 303 partially edentulous patients. *Clinical Implant Dentistry and Related Research*, 14(6), 839–851. <https://doi.org/10.1111/j.1708-8208.2012.00456.x>
- Calvo-Guirado, J. L., Delgado Ruiz, R. A., Ramirez-Fernandez, M. P., Abboud, M., Janjic, B., Sanchez, M., & de Val, J. E. (2016). Histological and histomorphometric analyses of narrow implants, crestal and subcrestally placed in severe alveolar atrophy: A study in foxhound dogs. *Clinical Oral Implants Research*, 27(4), 497–504. <https://doi.org/10.1111/clr.12569>
- Carcuac, O., Abrahamsson, I., Derks, J., Petzold, M., & Berglundh, T. (2020). Spontaneous progression of experimental peri-implantitis in augmented and pristine bone: A pre-clinical in vivo study. *Clinical Oral Implants Research*, 31(2), 192–200. <https://doi.org/10.1111/clr.13564>
- Cardaropoli, G., Lekholm, U., & Wennstrom, J. L. (2006). Tissue alterations at implant-supported single-tooth replacements: A 1-year prospective clinical study. *Clinical Oral Implants Research*, 17(2), 165–171. <https://doi.org/10.1111/j.1600-0501.2005.01210.x>
- Carmagnola, D., Araujo, M., Berglundh, T., Albrektsson, T., & Lindhe, J. (1999). Bone tissue reaction around implants placed in a compromised jaw. *Journal of Clinical Periodontology*, 26(10), 629–635. <https://doi.org/10.1034/j.1600-051x.1999.261001.x>
- Carmo Filho, L. C. D., Faot, F., Madruga, M. M., Marcello-Machado, R. M., Bordin, D., & Del Bel Cury, A. A. (2019). Effect of implant macrogeometry on peri-implant healing outcomes: A randomized clinical trial. *Clinical Oral Investigations*, 23(2), 567–575. <https://doi.org/10.1007/s00784-018-2463-5>
- Cesaretti, G., Lang, N. P., Salata, L. A., Schweikert, M. T., Gutierrez Hernandez, M. E., & Botticelli, D. (2015). Sub-crestal positioning of implants results in higher bony crest resorption: An experimental study in dogs. *Clinical Oral Implants Research*, 26(12), 1355–1360. <https://doi.org/10.1111/clr.12467>
- Chacun, D., Lafon, A., Courtois, N., Reveron, H., Chevalier, J., Margossian, P., Alves, A., Gritsch, K., & Grosgeat, B. (2021). Histologic and histomorphometric evaluation of new zirconia-based ceramic dental implants: A preclinical study in dogs. *Dental Materials*, 37(9), 1377–1389. <https://doi.org/10.1016/j.dental.2021.06.010>
- Chan, D., Pelekos, G., Ho, D., Cortellini, P., & Tonetti, M. S. (2019). The depth of the implant mucosal tunnel modifies the development and resolution of experimental peri-implant mucositis: A case-control study. *Journal of Clinical Periodontology*, 46(2), 248–255. <https://doi.org/10.1111/jcpe.13066>
- Chang, C. C., Greenspan, A., & Gershwin, M. E. (1993). Osteonecrosis: Current perspectives on pathogenesis and treatment. *Seminars in Arthritis and Rheumatism*, 23(1), 47–69.
- Chatvarathana, K., Thaworanunta, S., Seriwatanachai, D., & Wongsirichat, N. (2017). Correlation between the thickness of the crestal and buccolingual cortical bone at varying depths and implant stability quotients. *PLoS One*, 12(12), e0190293. <https://doi.org/10.1371/journal.pone.0190293>
- Checchi, V., Felice, P., Zucchelli, G., Barausse, C., Piattelli, M., Pistilli, R., Grandi, G., & Esposito, M. (2017). Wide diameter immediate post-extractive implants vs delayed placement of normal-diameter implants in preserved sockets in the molar region: 1-year post-loading outcome of a randomised controlled trial. *European Journal of Oral Implantology*, 10(3), 263–278.
- Chen, H., Liu, Z., Hu, X., Wu, B., & Gu, Y. (2021). Comparison of mandibular cross-sectional morphology between class I and class II subjects with different vertical patterns: Based on CBCT images and statistical shape analysis. *BMC Oral Health*, 21(1), 238. <https://doi.org/10.1186/s12903-021-01591-3>
- Chen, S. T., Darby, I. B., & Reynolds, E. C. (2007). A prospective clinical study of non-submerged immediate implants: Clinical outcomes and esthetic results. *Clinical Oral Implants Research*, 18(5), 552–562. <https://doi.org/10.1111/j.1600-0501.2007.01388.x>
- Cooper, L. F., De Kok, I. J., Rojas-Vizcaya, F., Pungpaong, P., & Chang, S. H. (2007). The immediate loading of dental implants. *The Compendium of Continuing Education in Dentistry*, 28(4), 216–225 quiz 226.
- Cooper, L. F., Reside, G., Stanford, C., Barwacz, C., Feine, J., Abi Nader, S., Scheyer, E. T., & McGuire, M. (2015). A multicenter randomized comparative trial of implants with different abutment interfaces to replace anterior maxillary single teeth. *The International Journal of Oral & Maxillofacial Implants*, 30(3), 622–632. <https://doi.org/10.11607/jomi.3772>
- Covani, U., Bortolaia, C., Barone, A., & Sbordone, L. (2004). Bucco-lingual crestal bone changes after immediate and delayed implant placement. *Journal of Periodontology*, 75(12), 1605–1612. <https://doi.org/10.1902/jop.2004.75.12.1605>
- Crespi, R., Toti, P., Covani, U., Crespi, G., & Menchini-Fabris, G. B. (2021). Clinical and radiographic evaluation of modified transalveolar two-step osteotome-mediated localized maxillary sinus elevation: A retrospective computed tomography study with a 3-year follow-up. *The International Journal of Oral & Maxillofacial Implants*, 36(3), 553–560. <https://doi.org/10.11607/jomi.8573>
- da Silva Pereira, S. L., Sallum, A. W., Casati, M. Z., Caffesse, R. G., Weng, D., Nociti, F. H., Jr., & Sallum, E. A. (2000). Comparison of bioabsorbable and non-resorbable membranes in the treatment of dehiscence-type defects. A histomorphometric study in dogs. *Journal of Periodontology*, 71(8), 1306–1314. <https://doi.org/10.1902/jop.2000.71.8.1306>

- Deporter, D. A., Watson, P. A., Pilliar, R. M., Howley, T. P., & Winslow, J. (1988). A histological evaluation of a functional endosseous, porous-surfaced, titanium alloy dental implant system in the dog. *Journal of Dental Research*, 67(9), 1190–1195. <https://doi.org/10.1177/00220345880670090801>
- Derks, J., Schaller, D., Hakansson, J., Wennstrom, J. L., Tomasi, C., & Berglundh, T. (2016). Effectiveness of implant therapy analyzed in a Swedish population: Prevalence of peri-implantitis. *Journal of Dental Research*, 95(1), 43–49. <https://doi.org/10.1177/0022034515608832>
- Di Raimondo, R., Sanz-Esporrin, J., Martin, I. S., Vignoletti, F., Nunez, J., Munoz, F., Haugen, H. J., & Sanz, M. (2021). Hard tissue volumetric and soft tissue contour linear changes at implants with different surface characteristics after experimentally induced peri-implantitis: An experimental in vivo investigation. *Clinical Oral Investigations*, 25(6), 3905–3918. <https://doi.org/10.1007/s00784-020-03720-8>
- Duong, M., Mealey, B. L., Walker, C., Al-Harathi, S., Prihoda, T. J., & Huynh-Ba, G. (2020). Evaluation of healing at molar extraction sites with and without ridge preservation: A three-arm histologic analysis. *Journal of Periodontology*, 91(1), 74–82. <https://doi.org/10.1002/JPER.19-0237>
- Dursun, E., Tulunoglu, I., Canpinar, P., Uysal, S., Akalin, F. A., & Tozum, T. F. (2012). Are marginal bone levels and implant stability/mobility affected by single-stage platform switched dental implants? A comparative clinical study. *Clinical Oral Implants Research*, 23(10), 1161–1167. <https://doi.org/10.1111/j.1600-0501.2011.02277.x>
- Farronato, D., Pasini, P. M., Orsina, A. A., Manfredini, M., Azzi, L., & Farronato, M. (2020). Correlation between buccal bone thickness at implant placement in healed sites and buccal soft tissue maturation pattern: A prospective three-year study. *Materials*, 13(3), 511. <https://doi.org/10.3390/ma13030511>
- Fenner, M., Vairaktaris, E., Stockmann, P., Schlegel, K. A., Neukam, F. W., & Nkenke, E. (2009). Influence of residual alveolar bone height on implant stability in the maxilla: An experimental animal study. *Clinical Oral Implants Research*, 20(8), 751–755. <https://doi.org/10.1111/j.1600-0501.2008.01570.x>
- Fienitz, T., Schwarz, F., Ritter, L., Dreiseidler, T., Becker, J., & Rothamel, D. (2012). Accuracy of cone beam computed tomography in assessing peri-implant bone defect regeneration: A histologically controlled study in dogs. *Clinical Oral Implants Research*, 23(7), 882–887. <https://doi.org/10.1111/j.1600-0501.2011.02232.x>
- Finelle, G., Papadimitriou, D. E. V., Souza, A. B., Katebi, N., Gallucci, G. O., & Araujo, M. G. (2015). Peri-implant soft tissue and marginal bone adaptation on implant with non-matching healing abutments: Micro-CT analysis. *Clinical Oral Implants Research*, 26(4), e42–e46. <https://doi.org/10.1111/clr.12328>
- Fiorellini, J. P., Llobell, A., Norton, M. R., Sarmiento, H. L., Chang, Y. C., & Wada, K. (2020). Healed edentulous sites: Suitability for dental implant placement, need for secondary procedures, and contemporary implant designs. *The International Journal of Oral & Maxillofacial Implants*, 35(5), 924–930. <https://doi.org/10.11607/jomi.8215>
- Gehrke, S. A., Braganca, L. K., Velasco-Ortega, E., & Calvo-Guirado, J. L. (2018). Evaluation of dimensional behavior of peri-implant tissues in implants immediately exposed or submerged in fresh extraction and healed sites: A histological study in dogs. *International Journal of Implant Dentistry*, 4(1), 5. <https://doi.org/10.1186/s40729-018-0120-z>
- Glibert, M., Ostman, S., De Bruyn, H., & Ostman, P. O. (2018). The influence of initial hard and soft tissue dimensions on initial crestal bone loss of immediately loaded dental implants. *The International Journal of Periodontics & Restorative Dentistry*, 38(6), 873–878. <https://doi.org/10.11607/prd.3458>
- Grunder, U., Gracis, S., & Capelli, M. (2005). Influence of the 3-D bone-to-implant relationship on esthetics. *The International Journal of Periodontics & Restorative Dentistry*, 25(2), 113–119.
- Hooijmans, C. R., Rovers, M. M., de Vries, R. B., Leenaars, M., Ritskes-Hoitinga, M., & Langendam, M. W. (2014). SYRCL's risk of bias tool for animal studies. *BMC Medical Research Methodology*, 14, 43. <https://doi.org/10.1186/1471-2288-14-43>
- Hur, Y., Ogata, Y., Kim, D. W., Pham, C. M., Yoon, T. H., & Ogata, H. (2017). Bone resorption during submerged healing after guided bone regeneration: A prospective case series. *Implant Dentistry*, 26(6), 820–825. <https://doi.org/10.1097/ID.0000000000000686>
- Jemt, T., & Lekholm, U. (2003). Measurements of buccal tissue volumes at single-implant restorations after local bone grafting in maxillas: A 3-year clinical prospective study case series. *Clinical Implant Dentistry and Related Research*, 5(2), 63–70. <https://doi.org/10.1111/j.1708-8208.2003.tb00185.x>
- Jemt, T., & Lekholm, U. (2005). Single implants and buccal bone grafts in the anterior maxilla: Measurements of buccal crestal contours in a 6-year prospective clinical study. *Clinical Implant Dentistry and Related Research*, 7(3), 127–135. <https://doi.org/10.1111/j.1708-8208.2005.tb00056.x>
- Jonker, B. P., Wolvius, E. B., van der Tas, J. T., Tahmaseb, A., & Pijpe, J. (2020). Esthetics and patient-reported outcomes of implants placed with guided bone regeneration and complete native bone: A prospective controlled clinical trial. *The International Journal of Oral & Maxillofacial Implants*, 35(2), 406–414. <https://doi.org/10.11607/jomi.7751>
- Jung, R. E., Herzog, M., Wolleb, K., Ramel, C. F., Thoma, D. S., & Hammerle, C. H. (2017). A randomized controlled clinical trial comparing small buccal dehiscence defects around dental implants treated with guided bone regeneration or left for spontaneous healing. *Clinical Oral Implants Research*, 28(3), 348–354. <https://doi.org/10.1111/clr.12806>
- Katafuchi, M., Weinstein, B. F., Leroux, B. G., Chen, Y. W., & Daubert, D. M. (2018). Restoration contour is a risk indicator for peri-implantitis: A cross-sectional radiographic analysis. *Journal of Clinical Periodontology*, 45(2), 225–232. <https://doi.org/10.1111/jcpe.12829>
- Katranji, A., Misch, K., & Wang, H. L. (2007). Cortical bone thickness in dentate and edentulous human cadavers. *Journal of Periodontology*, 78(5), 874–878. <https://doi.org/10.1902/jop.2007.060342>
- Kim, D. G., Elias, K. L., Jeong, Y. H., Kwon, H. J., Clements, M., Brantley, W. A., Lee, D. J., & Han, J. S. (2016). Differences between buccal and lingual bone quality and quantity of peri-implant regions. *Journal of the Mechanical Behavior of Biomedical Materials*, 60, 48–55. <https://doi.org/10.1016/j.jmbbm.2015.12.036>
- Koutouzis, T., Koutouzis, G., Gadalla, H., & Neiva, R. (2013). The effect of healing abutment reconnection and disconnection on soft and hard peri-implant tissues: A short-term randomized controlled clinical trial. *The International Journal of Oral & Maxillofacial Implants*, 28(3), 807–814. <https://doi.org/10.11607/jomi.3022>
- Lee, J., Fiorini, T., Gamborena, I., Wenzel, B. A., Schupbach, P., Wikesjo, U. M., & Susin, C. (2016). Effect of platform shift/switch on Crestal bone levels and mucosal profile following flapless surgery and crestal/subcrestal implant placement. *Clinical Implant Dentistry and Related Research*, 18(1), 73–81. <https://doi.org/10.1111/cid.12243>
- Lee, J., Yoo, J. M., Amara, H. B., Lee, Y. M., Lim, Y. J., Kim, H., & Koo, K. T. (2019). Bone healing dynamics associated with 3 implants with different surfaces: Histologic and histomorphometric analyses in dogs. *Journal of Periodontal & Implant Science*, 49(1), 25–38. <https://doi.org/10.5051/jpis.2019.49.1.25>
- Li Manni, L., Lecloux, G., Rompen, E., Aouini, W., Shapira, L., & Lambert, F. (2020). Clinical and radiographic assessment of circular versus triangular cross-section neck implants in the posterior maxilla: A 1-year randomized controlled trial. *Clinical Oral Implants Research*, 31(9), 814–824. <https://doi.org/10.1111/clr.13624>
- Lin, D., Li, Q., Li, W., & Swain, M. (2009). Dental implant induced bone remodeling and associated algorithms. *Journal of the Mechanical Behavior of Biomedical Materials*, 2(5), 410–432. <https://doi.org/10.1016/j.jmbbm.2008.11.007>

- Lindhe, J., Bressan, E., Cecchinato, D., Corra, E., Toia, M., & Liljenberg, B. (2013). Bone tissue in different parts of the edentulous maxilla and mandible. *Clinical Oral Implants Research*, 24(4), 372–377. <https://doi.org/10.1111/clr.12064>
- Mankin, H. J. (1992). Nontraumatic necrosis of bone (osteonecrosis). *The New England Journal of Medicine*, 326(22), 1473–1479. <https://doi.org/10.1056/NEJM199205283262206>
- Marconcini, S., Giammarinaro, E., Toti, P., Alfonsi, F., Covani, U., & Barone, A. (2018). Longitudinal analysis on the effect of insertion torque on delayed single implants: A 3-year randomized clinical study. *Clinical Implant Dentistry and Related Research*, 20(3), 322–332. <https://doi.org/10.1111/cid.12586>
- Monje, A., Chappuis, V., Monje, F., Munoz, F., Wang, H. L., Urban, I. A., & Buser, D. (2019). The critical peri-implant buccal bone wall thickness revisited: An experimental study in the beagle dog. *The International Journal of Oral & Maxillofacial Implants*, 34(6), 1328–1336. <https://doi.org/10.11607/jomi.7657>
- Monje, A., Eick, S., Buser, D., & Salvi, G. E. (2021). Microbial and host-derived biomarker changes during ligature-induced and spontaneous peri-implantitis in the beagle dog. *Journal of Periodontal Research*, 56(1), 93–100. <https://doi.org/10.1111/jre.12797>
- Monje, A., Galindo-Moreno, P., Tozum, T. F., Suarez-Lopez del Amo, F., & Wang, H. L. (2016). Into the paradigm of local factors as contributors for Peri-implant disease: Short communication. *The International Journal of Oral & Maxillofacial Implants*, 31(2), 288–292. <https://doi.org/10.11607/jomi.4265>
- Monje, A., & Nart, J. (2022). Management and sequelae of dental implant removal. *Periodontology 2000*, 88(1), 182–200. <https://doi.org/10.1111/prd.12418>
- Moses, O., Pitaru, S., Artzi, Z., & Nemcovsky, C. E. (2005). Healing of dehiscence-type defects in implants placed together with different barrier membranes: A comparative clinical study. *Clinical Oral Implants Research*, 16(2), 210–219. <https://doi.org/10.1111/j.1600-0501.2004.01100.x>
- Nemcovsky, C. E., & Artzi, Z. (2002). Comparative study of buccal dehiscence defects in immediate, delayed, and late maxillary implant placement with collagen membranes: Clinical healing between placement and second-stage surgery. *Journal of Periodontology*, 73(7), 754–761. <https://doi.org/10.1902/jop.2002.73.7.754>
- Nir-Hadar, O., Palmer, M., & Soskolne, W. A. (1998). Delayed immediate implants: Alveolar bone changes during the healing period. *Clinical Oral Implants Research*, 9(1), 26–33. <https://doi.org/10.1034/j.1600-0501.1998.090104.x>
- Noelken, R., Donati, M., Fiorellini, J., Gellrich, N. C., Parker, W., Wada, K., & Berglundh, T. (2014). Soft and hard tissue alterations around implants placed in an alveolar ridge with a sloped configuration. *Clinical Oral Implants Research*, 25(1), 3–9. <https://doi.org/10.1111/clr.12079>
- Nohra, J., Dagher, M., Matni, G., Mokbel, N., Jobaili, E., & Naaman, N. (2018). Effect of primary stability and soft- and hard-tissue thickness on marginal bone loss: A prospective pilot study. *Implant Dentistry*, 27(5), 542–546. <https://doi.org/10.1097/ID.0000000000000810>
- Novaes, A. B., Jr., Suaid, F., Queiroz, A. C., Muglia, V. A., Souza, S. L., Palioto, D. B., Taba, M., Jr., & Grisi, M. F. (2012). Buccal bone plate remodeling after immediate implant placement with and without synthetic bone grafting and flapless surgery: Radiographic study in dogs. *The Journal of Oral Implantology*, 38(6), 687–698. <https://doi.org/10.1563/AAID-JOI-D-10-00176>
- Nowzari, H., Chee, W., Yi, K., Pak, M., Chung, W. H., & Rich, S. (2006). Scalloped dental implants: A retrospective analysis of radiographic and clinical outcomes of 17 NobelPerfect implants in 6 patients. *Clinical Implant Dentistry and Related Research*, 8(1), 1–10. <https://doi.org/10.2310/j.6480.2005.00034.x>
- Oda, Y., Mori, G., Sasaki, H., Furuya, Y., Ito, T., Iijima, T., Sekine, H., & Yajima, Y. (2021). Dimensional changes of buccal bone in the edentulous maxilla with telescopic-retained implant-supported fixed dental prostheses. *The Journal of Prosthetic Dentistry*. <https://doi.org/10.1016/j.prosdent.2021.08.006>
- Oeschger, C. E., Bosshardt, D. D., Roehling, S., Gahlert, M., Cochran, D. L., & Janner, S. F. M. (2020). Crestal bone response to loaded zirconia and titanium implants: A radiographic and histometric analysis in canines. *Clinical Oral Investigations*, 24(10), 3609–3617. <https://doi.org/10.1007/s00784-020-03235-2>
- Onem, E., Baksi, B. G., & Sogur, E. (2012). Changes in the fractal dimension, feret diameter, and lacunarity of mandibular alveolar bone during initial healing of dental implants. *The International Journal of Oral & Maxillofacial Implants*, 27(5), 1009–1013.
- Page, M. J., McKenzie, J. E., Bossuyt, P. M., Boutron, I., Hoffmann, T. C., Mulrow, C. D., Shamseer, L., Tetzlaff, J. M., Akl, E. A., Brennan, S. E., Chou, R., Glanville, J., Grimshaw, J. M., Hróbjartsson, A., Lalu, M. M., Li, T., Loder, E. W., Mayo-Wilson, E., McDonald, S., ... Moher, D. (2021). The PRISMA 2020 statement: An updated guideline for reporting systematic reviews. *International Journal of Surgery*, 88, 105906. <https://doi.org/10.1016/j.ijsu.2021.105906>
- Palombo, D., Rahmati, M., Vignoletti, F., Sanz-Esporrin, J., Haugen, H. J., & Sanz, M. (2021). Hard and soft tissue healing around implants with a modified implant neck configuration: An experimental in vivo preclinical investigation. *Clinical Oral Implants Research*, 32(9), 1127–1141. <https://doi.org/10.1111/clr.13812>
- Patil, Y. B., Asopa, S. J., Deepa, Goel, A., Jyoti, D., Somayaji, N. S., & Sabharwal, R. (2020). Influence of implant neck design on crestal bone loss: A comparative study. *Nigerian Journal of Surgery*, 26(1), 22–27. https://doi.org/10.4103/njs.NJS_28_19
- Penarrocha-Oltra, D., Demarchi, C. L., Maestre-Ferrin, L., Penarrocha-Diago, M., & Penarrocha-Diago, M. (2012). Comparison of immediate and delayed implants in the maxillary molar region: A retrospective study of 123 implants. *The International Journal of Oral & Maxillofacial Implants*, 27(3), 604–610.
- Pons, R., Carreno, M., Amerio, E., Gargallo-Albiol, J., Nart, J., & Monje, A. (2021). Hard tissue dimensional changes following implant removal due to peri-implantitis: A retrospective study. *Clinical Implant Dentistry and Related Research*, 23(3), 432–443. <https://doi.org/10.1111/cid.13004>
- Qahash, M., Susin, C., Polimeni, G., Hall, J., & Wikesjo, U. M. (2008). Bone healing dynamics at buccal peri-implant sites. *Clinical Oral Implants Research*, 19(2), 166–172. <https://doi.org/10.1111/j.1600-0501.2007.01428.x>
- Raes, S., Eghbali, A., Chappuis, V., Raes, F., De Bruyn, H., & Cosyn, J. (2018). A long-term prospective cohort study on immediately restored single tooth implants inserted in extraction sockets and healed ridges: CBCT analyses, soft tissue alterations, aesthetic ratings, and patient-reported outcomes. *Clinical Implant Dentistry and Related Research*, 20(4), 522–530. <https://doi.org/10.1111/cid.12613>
- Rodriguez-Ortiz, G., Chen, S., Davies, H., Fitzgerald, W., & Darby, I. (2021). Early implant placement in ridge preserved extraction sockets: A pre-clinical in vivo study. *Clinical Oral Implants Research*, 32(6), 745–755. <https://doi.org/10.1111/clr.13744>
- Roush, J. K., Howard, P. E., & Wilson, J. W. (1989). Normal blood supply to the canine mandible and mandibular teeth. *American Journal of Veterinary Research*, 50(6), 904–907.
- Roux, S., & Orcel, P. (2000). Bone loss. Factors that regulate osteoclast differentiation: An update. *Arthritis Research*, 2(6), 451–456. <https://doi.org/10.1186/ar127>
- Sanz-Martin, I., Vignoletti, F., Nunez, J., Permy, M., Munoz, F., Sanz-Esporrin, J., Fierravanti, L., Shapira, L., & Sanz, M. (2017). Hard and soft tissue integration of immediate and delayed implants with a modified coronal macrodesign: Histological, micro-CT and volumetric soft tissue changes from a pre-clinical in vivo study. *Journal of Clinical Periodontology*, 44(8), 842–853. <https://doi.org/10.1111/jcpe.12747>
- Sarment, D. P., & Meraw, S. J. (2008). Biological space adaptation to implant dimensions. *The International Journal of Oral & Maxillofacial Implants*, 23(1), 99–104.

- Schliephake, H., Wichmann, M., Donnerstag, F., & Vogt, S. (2003). Imaging of periimplant bone levels of implants with buccal bone defects. *Clinical Oral Implants Research*, 14(2), 193–200. <https://doi.org/10.1034/j.1600-0501.2003.140209.x>
- Schropp, L., Wenzel, A., Spin-Neto, R., & Stavropoulos, A. (2015). Fate of the buccal bone at implants placed early, delayed, or late after tooth extraction analyzed by cone beam CT: 10-year results from a randomized, controlled, clinical study. *Clinical Oral Implants Research*, 26(5), 492–500. <https://doi.org/10.1111/clr.12424>
- Schwarz, F., Herten, M., Sager, M., Wieland, M., Dard, M., & Becker, J. (2007). Bone regeneration in dehiscence-type defects at chemically modified (SLActive) and conventional SLA titanium implants: A pilot study in dogs. *Journal of Clinical Periodontology*, 34(1), 78–86. <https://doi.org/10.1111/j.1600-051X.2006.01008.x>
- Schwarz, F., Sager, M., Golubovic, V., Iglhaut, G., & Becker, K. (2016). Horizontal mucosal thickness at implant sites as it correlates with the integrity and thickness of the buccal bone plate. *Clinical Oral Implants Research*, 27(10), 1305–1309. <https://doi.org/10.1111/clr.12747>
- Schwarz, F., Sahm, N., & Becker, J. (2012). Impact of the outcome of guided bone regeneration in dehiscence-type defects on the long-term stability of peri-implant health: Clinical observations at 4 years. *Clinical Oral Implants Research*, 23(2), 191–196. <https://doi.org/10.1111/j.1600-0501.2011.02214.x>
- Scipioni, A., Bruschi, G. B., Giargia, M., Berglundh, T., & Lindhe, J. (1997). Healing at implants with and without primary bone contact. An experimental study in dogs. *Clinical Oral Implants Research*, 8(1), 39–47. <https://doi.org/10.1111/j.1600-0501.1997.tb00006.x>
- Serrano, B., Sanz-Sanchez, I., Serrano, K., Montero, E., & Sanz, M. (2022). One-year outcomes of dental implants with a hybrid surface macro-design placed in patients with history of periodontitis: A randomized clinical trial. *Journal of Clinical Periodontology*, 49(2), 90–100. <https://doi.org/10.1111/jcpe.13575>
- Souza, A. B., Alshihri, A., Kammerer, P. W., Araujo, M. G., & Gallucci, G. O. (2018). Histological and micro-CT analysis of peri-implant soft and hard tissue healing on implants with different healing abutments configurations. *Clinical Oral Implants Research*, 29(10), 1007–1015. <https://doi.org/10.1111/clr.13367>
- Spray, J. R., Black, C. G., Morris, H. F., & Ochi, S. (2000). The influence of bone thickness on facial marginal bone response: Stage 1 placement through stage 2 uncovering. *Annals of Periodontology*, 5(1), 119–128. <https://doi.org/10.1902/annals.2000.5.1.119>
- Sterne, J. A. C., Savovic, J., Page, M. J., Elbers, R. G., Blencowe, N. S., Boutron, I., Cates, C. J., Cheng, H.-Y., Corbett, M. S., Eldridge, S. M., Emberson, J. R., Hernán, M. A., Hopewell, S., Hróbjartsson, A., Junqueira, D. R., Jüni, P., Kirkham, J. J., Lasserson, T., Li, T., ... Higgins, J. P. T. (2019). RoB 2: A revised tool for assessing risk of bias in randomised trials. *BMJ*, 366, l4898. <https://doi.org/10.1136/bmj.l4898>
- Suaid, F. A., Novaes, A. B., Jr., Queiroz, A. C., Muglia, V. A., Almeida, A. L., & Grisi, M. F. (2014). Buccal bone plate remodeling after immediate implants with or without synthetic bone grafting and flapless surgery: A histomorphometric and fluorescence study in dogs. *Clinical Oral Implants Research*, 25(2), e10–e21. <https://doi.org/10.1111/clr.12036>
- Sutter, F., Schroeder, A., & Buser, D. (1988). [New ITI implant concept—technical aspects and methods (I)]. *Die Quintessenz*, 39(11), 1875–1890.
- Tal, H., Artzi, Z., Moses, O., Nemcovsky, C. E., & Kozlovsky, A. (2001). Spontaneous early exposure of submerged endosseous implants resulting in crestal bone loss: A clinical evaluation between stage I and stage II surgery. *The International Journal of Oral & Maxillofacial Implants*, 16(4), 514–521.
- Tanaka, K., Sailer, I., Iwama, R., Yamauchi, K., Nogami, S., Yoda, N., & Takahashi, T. (2018). Relationship between cortical bone thickness and implant stability at the time of surgery and secondary stability after osseointegration measured using resonance frequency analysis. *Journal of Periodontal & Implant Science*, 48(6), 360–372. <https://doi.org/10.5051/jpis.2018.48.6.360>
- Tarnow, D. (1993). Esthetic excellence with the single-tooth implant. *Dental Economics*, 83(3), 80–82.
- Temmerman, A., Keestra, J. A., Coucke, W., Teughels, W., & Quirynen, M. (2015). The outcome of oral implants placed in bone with limited bucco-oral dimensions: A 3-year follow-up study. *Journal of Clinical Periodontology*, 42(3), 311–318. <https://doi.org/10.1111/jcpe.12376>
- Thoma, D. S., Lim, H. C., Paeng, K. W., Jung, U. W., Hammerle, C. H. F., & Jung, R. E. (2019). Tissue integration of zirconia and titanium implants with and without buccal dehiscence defects—A histologic and radiographic preclinical study. *Clinical Oral Implants Research*, 30(7), 660–669. <https://doi.org/10.1111/clr.13451>
- van Eekeren, P., van Elsas, P., Tahmaseb, A., & Wismeijer, D. (2017). The influence of initial mucosal thickness on crestal bone change in similar macrogeometrical implants: A prospective randomized clinical trial. *Clinical Oral Implants Research*, 28(2), 214–218. <https://doi.org/10.1111/clr.12784>
- Vera, C., De Kok, I. J., Chen, W., Reside, G., Tyndall, D., & Cooper, L. F. (2012). Evaluation of post-implant buccal bone resorption using cone beam computed tomography: A clinical pilot study. *The International Journal of Oral & Maxillofacial Implants*, 27(5), 1249–1257.
- Vignoletti, F., Sanz-Esporrin, J., Sanz-Martin, I., Nunez, J., Luengo, F., & Sanz, M. (2019). Ridge alterations after implant placement in fresh extraction sockets or in healed crests: An experimental in vivo investigation. *Clinical Oral Implants Research*, 30(4), 353–363. <https://doi.org/10.1111/clr.13421>
- Wadamoto, M., Akagawa, Y., Sato, Y., & Kubo, T. (1996). The three-dimensional bone interface of an osseointegrated implant. I: A morphometric evaluation in initial healing. *The Journal of Prosthetic Dentistry*, 76(2), 170–175. [https://doi.org/10.1016/s0022-3913\(96\)90302-9](https://doi.org/10.1016/s0022-3913(96)90302-9)
- Wells, G. A., Shea, B., O'Connell, D., Peterson, J., Welch, V., Losos, M., & Tugwell, P. (2014). The Newcastle–Ottawa Scale (NOS) for assessing the quality of non-randomized studies in meta-analysis. *Applied Engineering in Agriculture*. https://www.ohri.ca/programs/clinical_epidemiology/oxford.asp
- Windael, S., Collaert, B., De Buyser, S., De Bruyn, H., & Vervaeke, S. (2021). Early peri-implant bone loss as a predictor for peri-implantitis: A 10-year prospective cohort study. *Clinical Implant Dentistry and Related Research*, 23(3), 298–308. <https://doi.org/10.1111/cid.13000>
- Yi, H. Y., Park, Y. S., Pippenger, B. E., Lee, B., Miron, R. J., & Dard, M. (2017). Dimensional changes following immediate and delayed implant placement: A histomorphometric study in the canine. *The International Journal of Oral & Maxillofacial Implants*, 32(3), 541–546. <https://doi.org/10.11607/jomi.5145>
- Yoda, N., Zheng, K., Chen, J., Li, W., Swain, M., Sasaki, K., & Li, Q. (2017). Bone morphological effects on post-implantation remodeling of maxillary anterior buccal bone: A clinical and biomechanical study. *Journal of Prosthodontic Research*, 61(4), 393–402. <https://doi.org/10.1016/j.jpor.2016.12.010>

SUPPORTING INFORMATION

Additional supporting information can be found online in the Supporting Information section at the end of this article.

How to cite this article: Monje, A., Rocuzzo, A., Buser, D., & Wang, H.-L. (2023). Influence of buccal bone wall thickness on the peri-implant hard and soft tissue dimensional changes: A systematic review. *Clinical Oral Implants Research*, 34(Suppl. 26), 4–27. <https://doi.org/10.1111/clr.14177>