

Prosthetic Management of Implants in the Esthetic Zone

Frank Higginbottom, DDS¹/Urs Belser, DMD²/John D. Jones, DDS³/Scott E. Keith, DDS, MS⁴

The purpose of this article is to review and project treatment procedures for areas of esthetic concern. The authors were participants in a consensus conference sponsored by ITI and held in August 2003 in Gstaad, Switzerland. This article deals with the basic prosthetic/restorative aspects in implant esthetics. It is based on a literature review performed by 16 participants from Group 2 (Buser et al) in this section of the Journal. INT J ORAL MAXILLOFAC IMPLANTS 2004;19(SUPPL):62-72

Key words: dental implants, esthetics, implant abutments, implant diameter, provisional restorations

An esthetic area can be defined as any area to be restored that is visible in the patient's full smile. An esthetic implant restoration is one that resembles a natural tooth in all aspects.¹⁻⁵ The position in which the implant is placed is of utmost importance, and the implant should be thought of as an extension of the clinical crown into the alveolar bone.⁶ This is only possible if the implant is correctly located in all 3 dimensions: apicocoronally, mesiodistally, and faciolingually.¹ Any deviation from these dimensions results in a problem the dental technician can scarcely solve. Choosing the appropriate time to place the implant into function

is the surgeon's choice. The surgeon's judgment precludes timetables and other potential standards.^{7,8}

CONSIDERATIONS FOR ESTHETIC SITES

The restorative dentist needs to work with the surgeon, and both need to understand that certain principles are prerequisites for esthetic success.^{4,9-11} These may include but are not limited to the following:

1. The edentulous site must first exhibit adequate bone volume for the placement of a dental implant. If the site is deficient, there are many techniques that can be used for site development, some of which may be accomplished at time of implant placement.¹² In other instances it is best to augment the site in a separate procedure.
2. The placement position needs to be precise, as has been described in previous articles.
3. The abutment interface or connection needs to be stable.
4. The microgap between the implant and the abutment must be as small as possible.¹³

¹Associate Clinical Professor, Baylor College of Dentistry, Dallas, Texas.

²Professor and Chairman, Department of Prosthodontics, School of Dental Medicine, University of Geneva, Switzerland.

³Associate Professor, Department of Prosthodontics, University of Texas Health Science Center, San Antonio, Texas.

⁴Private Practice, San Francisco, California.

Correspondence to: Dr Frank L. Higginbottom, 3600 Gaston, Suite 1107, Dallas, Texas 75246. Fax: +214-823-1370. E-mail: bottom@dallasesthetics.com

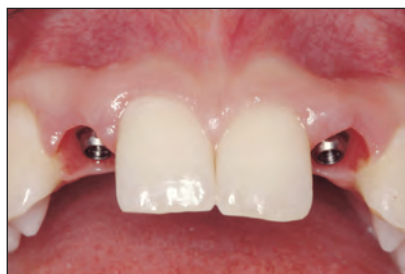

Fig 1 Peri-implant space created around root-form dental implants.

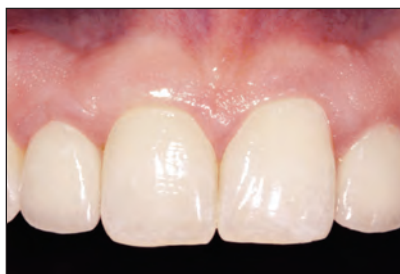

Fig 2 Photograph of metal-ceramic implant-supported restorations in lateral incisor positions 7 years postplacement.

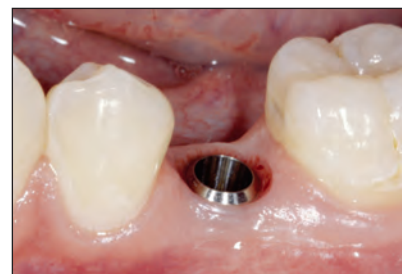

Fig 3 A flat gingival scallop in a mandibular posterior quadrant provides a shallow gingival crown margin interproximally.

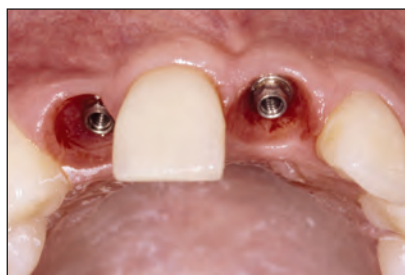

Fig 4 Anterior implant placement dictates deeper placement and a deep interproximal margin.

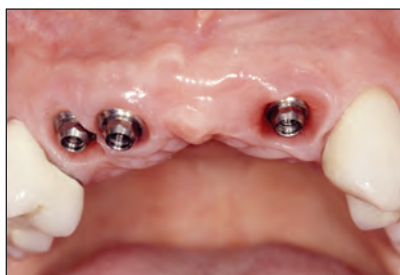

Fig 5 Multiple missing tooth gaps do not require an implant for each missing tooth.

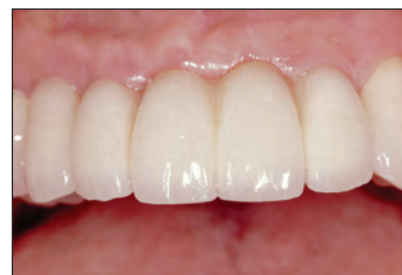

Fig 6 Fixed partial denture replacing multiple missing teeth.

5. Esthetic restorations should be designed to have an appropriate “emergence profile”¹⁴ and not a ridge lap.
6. The restoration should have the same appearance as the adjacent teeth (Figs 1 and 2).

Implant Placement Considerations

Placement depth is an important aspect of an esthetic restoration. There must be good communication between the surgeon and the restorative clinician relative to proper implant positioning. In the posterior quadrants, where the gingival scallop is relatively flat, the implant shoulder may be at the gingival level or only slightly below it (Fig 3). However, depending on tissue thickness, implants may be placed slightly deeper. This does not present a problem in most posterior situations, because a flat gingival scallop allows access for cement removal and oral hygiene by the patient.

In most esthetic areas the implant shoulder is located 2 mm below the midfacial gingival margin (Fig 4). In these sites the gingival scallop is usually more pronounced, resulting in an interproximal margin as deep as 5 to 7 mm. This shoulder location makes seating of the restoration and cement removal difficult. Therefore, the treatment of choice should be screw-retained restorations.

The placement of single implant restorations is a well-documented and predictable procedure.^{15–19}

Therefore, an implant can be the preferred treatment option in most patients. Multiple missing teeth require greater attention to detail and treatment planning.²⁰ Spacing issues and the number of implants are critical.^{21–23} Generally, it is accepted that adjacent implants are a treatment challenge because interimplant bone resorption leads to a lack of soft tissue support^{24–26} (Fig 5). In some instances involving multiple missing teeth, an implant-supported fixed partial denture may be a more desirable choice. Better esthetic results can be achieved with ovate pontics than would be possible with adjacent implants^{12,27} (Fig 6).

Interim Restorations During the Healing Period

Interim restorations may not be required outside of the esthetic zone. In the esthetic zone, there are several treatment options for patients requiring interim tooth replacement.²⁸ A simple solution for a provisional restoration at the surgery, or to serve the patient until the restorative practitioner is seen, is to place a vacuform matrix with a denture tooth. The second and most frequently used option is an interim removable partial denture (Figs 7a to 7c). It is easily fabricated and simple for the surgeon or restorative clinician to fit. Care must be taken to prevent the gingival portion of the interim partial denture from contacting an exposed healing abutment. A third option, for the more demanding

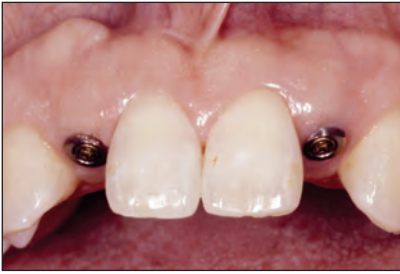

Fig 7a Single-tooth gaps in the anterior maxilla.

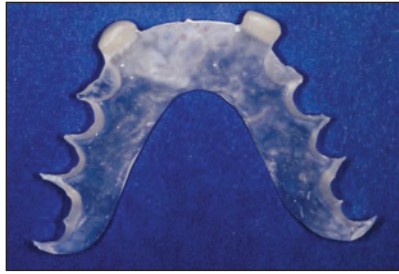


Fig 7b Interim removable partial denture.

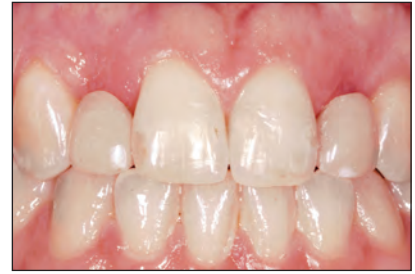

Fig 7c Interim removable partial denture in place.

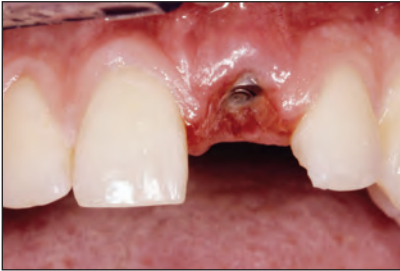

Fig 8a (Left) Healing implant in central incisor position.

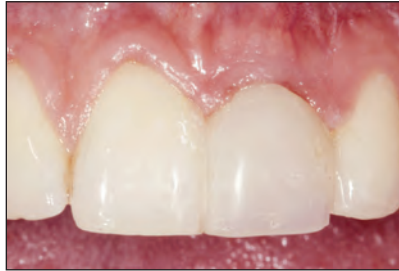

Fig 8b (Right) Composite pontic bonded to adjacent teeth.

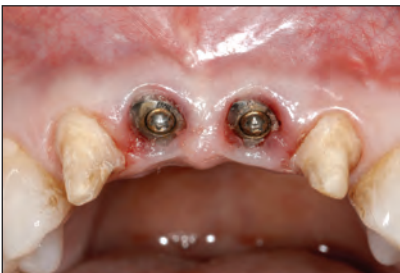

Fig 9a Prepared teeth adjacent to integrating implants.

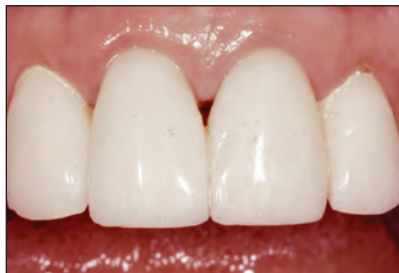

Fig 9b Fixed provisional restoration in place.




Fig 10 Straumann ratchet and torque control device.

patient who does not want a removable prosthesis, is a bonded restoration. This type of restoration may be appropriate for a patient who will require long healing periods. A denture tooth, composite pontic, or the clinical crown of the previously failed restoration may be bonded to the adjacent teeth (Figs 8a and 8b). Finally, a provisional fixed partial denture may also be used in instances where the adjacent teeth are to receive crowns as part of the final treatment (Figs 9a and 9b).

Abutment Connections

All Straumann abutments (Waldenburg, Switzerland) are seated and tightened to 35 Ncm.²⁹ Tightening of the abutment is performed using the appropriate abutment driver or the SCS screwdriver (Straumann) in conjunction with a ratchet and torque control device (Fig 10). The healing abutment is removed and the internal configuration of

the implant is irrigated with an appropriate disinfectant. The implant is rinsed with water and air dried, and the abutment is placed without adhesive or cement. Abutment connections should be performed without local anesthesia. The patient may experience sensitivity during the abutment-tightening procedure, and the clinician has the opportunity to stop prior to mobilization of the implant. In these instances, which are extremely rare, the patient can return after 1 month and the abutment can then be tightened to 35 Ncm without incident.

RESTORATIVE OPTIONS/ ABUTMENT SELECTION

There are multiple abutments for use in esthetic areas. The primary concern is accurate fit of the crown margin to the implant shoulder, with no

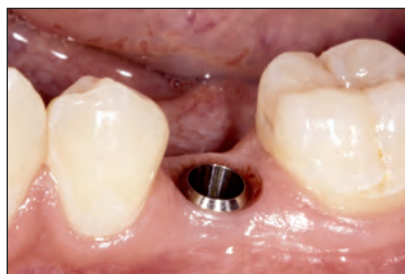

Fig 11a The healing abutment is removed from implant after 6 weeks of

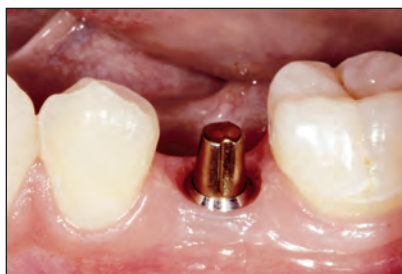

Fig 11b A 4-mm solid abutment is placed as the restorative abutment.

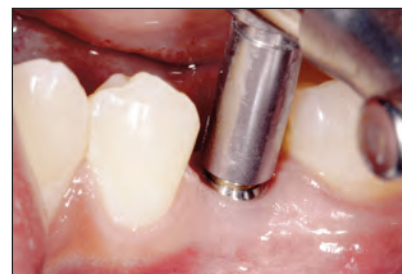

Fig 11c Solid abutment driver and ratchet with torque control device tightening the solid abutment to 35 Ncm.

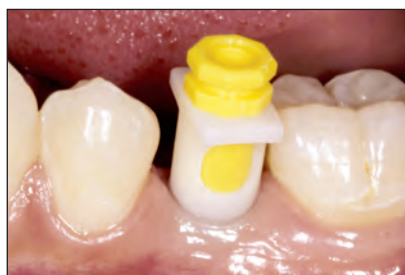

Fig 11d The impression coping is snapped into place and the appropriate positioning cylinder is seated.

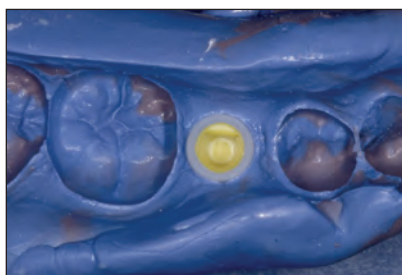


Fig 11e The impression coping is picked up in a 2-phase polyvinyl impression material.

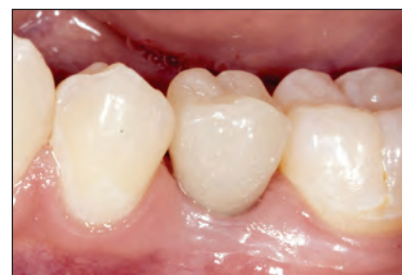

Fig 11f A provisional restoration is placed during the period of fabricating a definitive restoration.

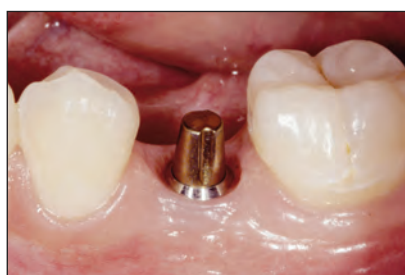

Fig 11g The provisional restoration has shaped the peri-implant soft tissues. This becomes more important the deeper the implant shoulder is placed.

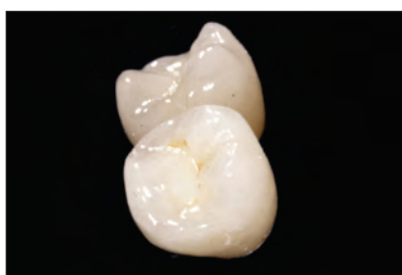


Fig 11h An all-ceramic definitive restoration is fabricated.

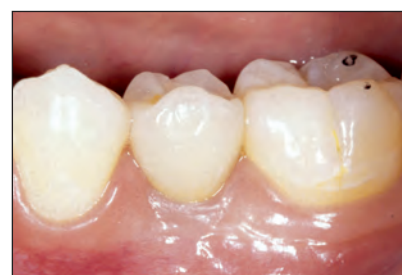

Fig 11i The definitive restoration is cemented into place.

inclusion of cement.³⁰ There are several options for accomplishing this goal. Guidelines for selection can sometimes be standardized.

The solid abutment is the most frequently used abutment in the Straumann Implant System. It is the primary abutment for posterior single and multiple tooth restorations in the partially edentulous patient. It may also be used in the anterior region with the understanding that the interproximal margin is usually deep. The solid abutment is inserted into the implant after removal of the healing abutment. The abutment is torqued to 35 Ncm with the solid abutment driver and torque controller (Figs 11a to 11c). An impression cap is inserted and the positioning cylinder is seated (Fig 11d). An impression is made and sent to the laboratory for crown fabrication (Fig 11e). The solid abutment may be protected with a

protective cap or a provisional restoration can be fabricated (Fig 11f). Placement of a customized provisional restoration is advisable in esthetic situations to shape the gingival tissues (Fig 11g). A definitive restoration is fabricated and returned for placement (Figs 11h and 11i). The solid abutment is the only abutment for which an impression is made directly in the mouth. If the solid abutment is not chosen, a direct implant-level impression is preferred.

Impressions or indexing of the implant may be performed at any time. Typically, the implant is indexed either at the time of surgery or at the start of the restorative procedure. The 2-part Straumann implant has an internal octagon/Morse taper, termed *synOcta*.²⁹ This internal feature allows the implant to be indexed directly with the *synOcta* screw-retained impression coping for an open-tray

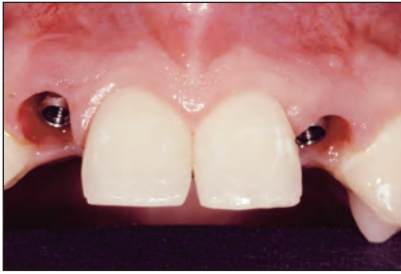

Fig 12a (Left) synOcta 1.5-mm abutments are seated and torqued to 35 Ncm.

Fig 12b (Right) Cast custom abutments, which control angulation and margin level for a cemented crown.

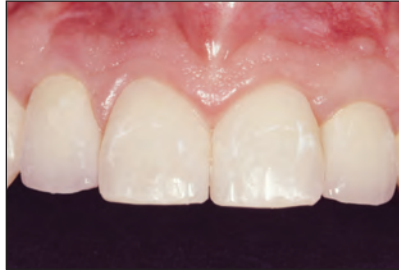
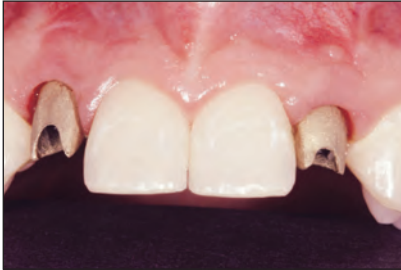
Fig 12c (Left) Custom abutments are seated with 4-mm occlusal screws.

Fig 12d (Right) Definitive cemented restorations.

impression, or the impression cap can be used in conjunction with the synOcta positioning cylinder for a closed-tray impression technique. If indexing is performed at the time of implant placement, the surgeon or restorative clinician places the appropriate impression coping. Using the surgical template or a separate indexing template, the impression coping is fixed to the template device with autopolymerizing resin. The laboratory will retrofit a synOcta analog to a presurgical cast. This new working cast can then be used to fabricate a provisional restoration to be delivered at the time of reopening surgery or when the restorative procedure is initiated. Neither method of making an implant-level impression obligates the restorative clinician to select the abutment during the operation. Abutment selection is made on the working cast in the laboratory. This process requires collaboration between the laboratory technician and the clinician.

The synOcta 1.5-mm abutment is the primary abutment of choice for esthetic screw-retained restorations. This technique provides a machined connection to the implant and avoids the problem of cement left deep interproximally. The abutment may be placed in the mouth at the start of the restorative procedure and an impression made, similar to what has been done with the standard octabutment. An implant-level impression may also be made as previously described, with the abutment selected in the laboratory. The laboratory technician selects the appropriate gold coping and applies wax and casts a metal framework. Porcelain is applied and baked to the substructure and a definitive crown is produced. The crown and the abut-

ment are returned to the clinician for placement. The abutment is seated and tightened to 35 Ncm. The crown is placed and retained by a 4-mm SCS occlusal screw tightened to 15 Ncm.

If the anatomy of the anterior maxilla and the resulting implant axis does not allow a direct screw-retained crown to be attached to the implant, angular corrections are necessary. There are many options to correct angulation.

The synOcta 1.5-mm abutment is chosen in the laboratory and placed on the working cast. Wax is added to a gold coping to simulate the finish line of a prepared tooth, and a casting is produced. This casting is the custom abutment for a cemented crown. The custom abutment is placed on the implant over the abutment. This screw-retained casting provides a machined margin at the microgap level while correcting angulations, and raises the marginal termination to be compatible for a cemented restoration. The custom abutment is secured by a 4-mm SCS occlusal screw tightened to 15 Ncm (Figs 12a to 12d).

The transverse screw abutment (TS) also provides a method of angulation correction, using a lingual path of insertion for the hexagonal fixation screw. The TS abutment is fitted to the laboratory working cast, and a transverse screw coping of gold or delrin is seated. The coping is modified with wax and cast to form a metal framework for porcelain application. The definitive crown and the TS abutment are then returned to the clinician for placement. Using an abutment index, the TS abutment is placed within the implant and torqued to 35 Ncm. The crown is placed and secured with a lingual set

Fig 13a (Left) The transverse screw abutment (TS) is seated and torqued to 35 Ncm.

Fig 13b (Right) The definitive crown, with hex set screw and screwdriver, ready for placement in the mouth.

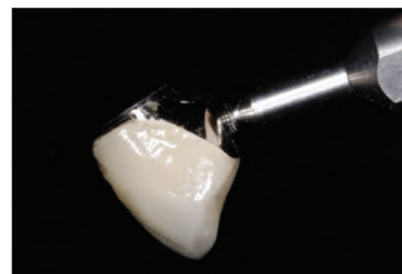
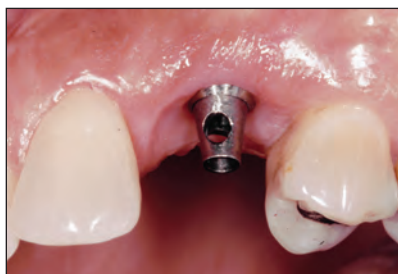
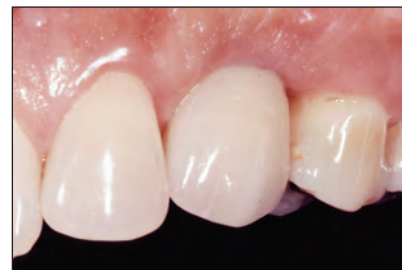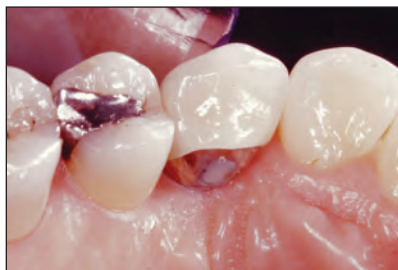Fig 13c (Left) Palatal view of the seated TS restoration. The set screw is covered with rubber-sep and composite resin.

Fig 13d (Right) Facial appearance of the final TS restoration.



screw and then hand tightened (to 10 to 15 Ncm) utilizing the TS driver (Figs 13a to 13d).

The ceramic component can also correct angulation if used as a meso-structure—yet another option for esthetic situations. Since it is tooth colored, this coping may also be valuable in areas with thin gingival tissues that would transmit unfavorable color from metallic substructures. The ceramic coping is selected in the laboratory after an implant-level impression is fitted with a synOcta 1.5-mm analog. The ceramic component is provided in the form of an immature aluminous porcelain blank, which can be prepared to provide a direct base for porcelain application or as a custom abutment for a cemented crown. An all-ceramic crown is fabricated for cementation. If screw access is favorable, the ceramic component is suitable for direct porcelain application and a screw-retained implant restoration is created. The ceramic component or crown is secured to a synOcta 2.5-mm abutment on the implant by a special 4-mm occlusal screw tightened to 35 Ncm. Screw access openings are sealed with an appropriate material (Figs 14a to 14e).

The meso-abutment is a machinable abutment made of titanium whose connection fits directly into the implant body. It may be used in place of a custom abutment on a synOcta 1.5-mm abutment. To restore a site using the meso-abutment, the laboratory technician places the abutment on the working cast and shapes it to correct any angulation problems and to alter the marginal level for a cemented restoration. A cementable crown is fabricated and returned to the clinician with the modified meso-abutment. The meso-abutment is seated into the implant and the

abutment screw is torqued to 35 Ncm. The definitive crown is then cemented (Figs 15a to 15e).

A cementable approach may also be initiated in the laboratory. The synOcta 5.5-mm abutment can be used to fabricate a definitive restoration and be delivered at the same time the definitive restoration is placed (Figs 16a to 16c).

Abutments angled at 15 and 20 degrees may also be chosen in the laboratory using an abutment selection kit and an implant-level laboratory cast. These abutments are used for cementation and have properties similar to those of solid abutments, but they are selected in the laboratory. The angled abutment may also be used for screw retention, which solves the cement removal problem in instances of deep margin placement (Figs 17a to 17c).

Cementation Procedures

Cemented crown margins placed at the implant shoulder—such as those fabricated on solid abutments, the synOcta 5.5-mm abutments, and the angled abutments—must be handed carefully. These crown margins do not have the same marginal integrity as those made on premachined gold copings. In anterior esthetic applications, these crown margins may also be quite deep interproximally. Care needs to be taken to avoid leaving any cement during the cementation procedure. Cement exclusion may be addressed by careful application of minimal amounts of cement.^{29,31,32} It is also helpful, prior to placing a cemented restoration in the mouth, to apply cement to the crown and place it on an analog or practice abutment. Excess cement is extruded and can be removed while the crown is on

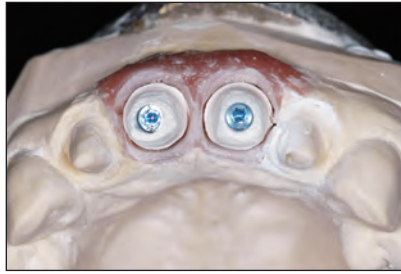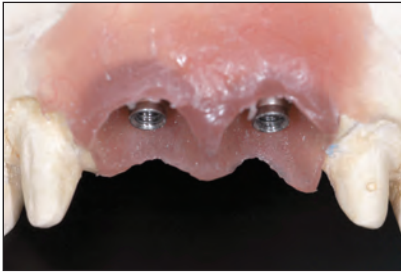


Fig 14a (Left) Provisional restoration generated by the soft tissue model, with abutment in place.

Fig 14b (Right) Immature ceramic is shaped to form a custom abutment.

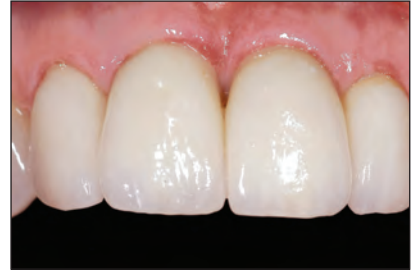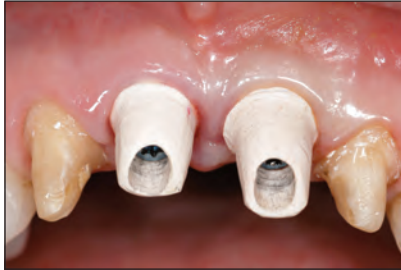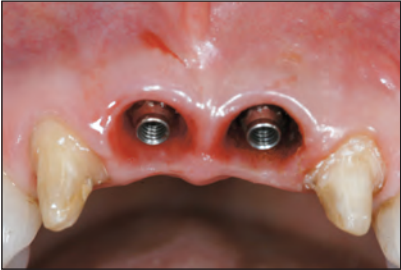


Fig 14c Abutments seated and tightened to 35 Ncm.

Fig 14d Ceramic components seated with special 4-mm occlusal screw. The occlusal screw is tightened to 15 Ncm.

Fig 14e Final appearance of all-ceramic restorations.

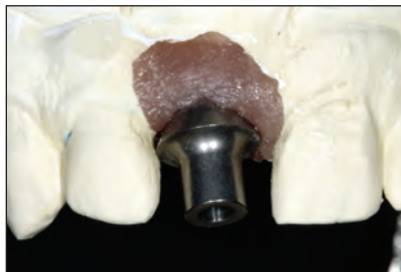

Fig 15a (Left) The meso-abutment. Note that this is a 2-piece abutment that fits directly into the implant. This provides the same function as the synOcta 1.5-mm abutment and a cast custom abutment.

Fig 15b (Right) Unaltered meso-abutment on a soft tissue working cast.

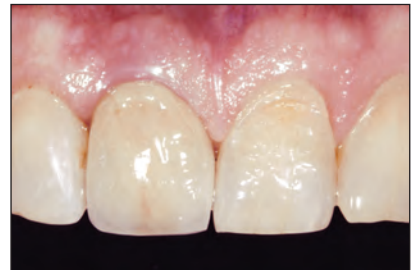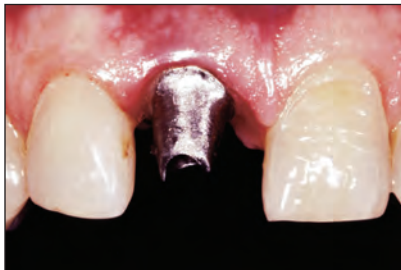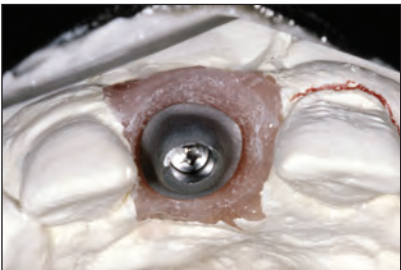


Fig 15c The meso-abutment is shaped to control angulation and cement line.

Fig 15d The meso-abutment seated in the mouth and torqued to 35 Ncm. This serves as a customized base for a cemented crown.

Fig 15e Definitive cemented porcelain-fused-to-metal restoration. Angulation and cement line are controlled with one component.

the analog. The crown is immediately removed from the analog and placed in the mouth without the application of any additional cement.

PROVISIONAL AND DEFINITIVE RESTORATIONS

It is preferable to place provisional restorations on the implant at the time the restorative procedure is

started.³³⁻³⁵ However, after impression making, it is also possible for the clinician to merely replace the healing abutment and temporary restoration that have been in place during the healing period. The most important benefit of provisionalization at the start of the restorative procedure is shaping of the peri-implant tissues.³⁶ This process will establish a natural and esthetic soft tissue form that will determine guidelines for laboratory fabrication of an anatomically appropriate soft tissue model. The provisional

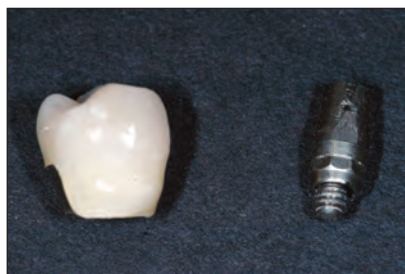

Fig 16a The definitive crown and abutment will be placed at the same time by the clinician. They will fit in the mouth exactly as on the laboratory working cast.

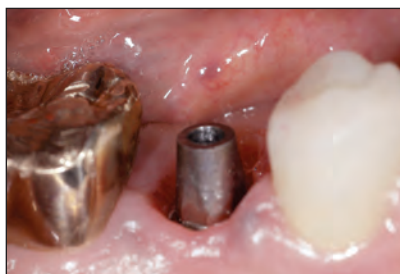

Fig 16b The 5.5-mm abutment placed in the mouth. The abutment is torqued to 35 Ncm.

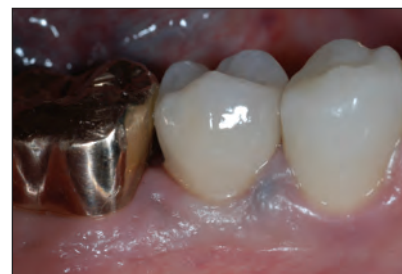

Fig 16c Definitive porcelain-fused-to-metal restoration cemented into place.

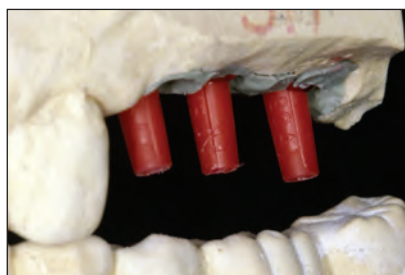

Fig 17a Three angled abutments are selected using the abutment selection kit and the working casts in the laboratory.

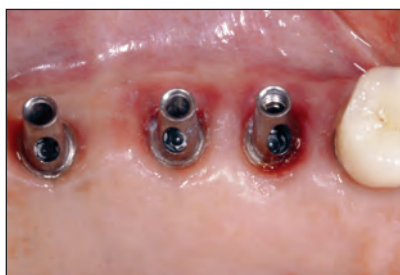

Fig 17b Two 15A and one 20A abutments are selected by the laboratory technician and placed in the mouth. The abutment screws are tightened to 35 Ncm.

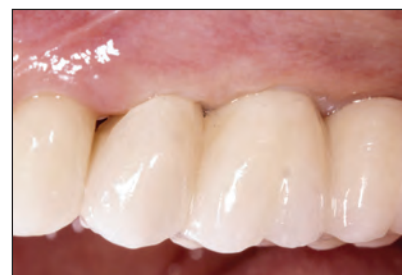

Fig 17c Definitive restoration cemented over the three angled abutments.

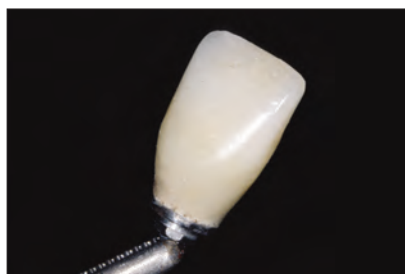

Fig 18a The provisional restoration is finalized and polished in the laboratory.

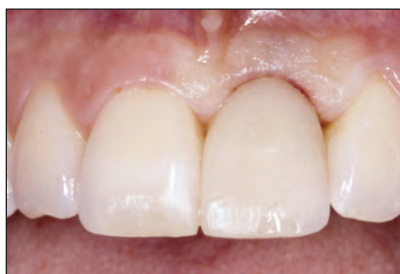

Fig 18b The completed provisional restoration is seated for guided tissue shaping.

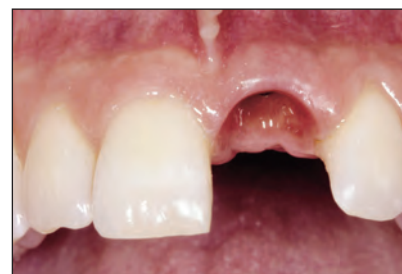

Fig 18c The shaped peri-implant space is ready to accommodate an emergence profile restoration.

restoration may be fabricated in the laboratory on a temporization coping. The clinician may also use the temporization coping chairside to fabricate a screw-retained provisional restoration. In some instances a solid abutment may also be used to support a cemented provisional restoration. In addition, with esthetic implant placement, it is difficult to fully seat a definitive restoration if the peri-implant tissues have not been shaped with emergence-profile provisional restorations (Figs 18a to 18c).

The previously mentioned restorative abutment options have little validity in esthetic situations if the laboratory does not have an accurate soft tissue

model with which to plan and fabricate the final termination point of the definite restoration and its contour. An anatomically correct cast may be fabricated by transferring the subgingival contours of the provisional restoration to the working cast. This may be accomplished with a custom impression coping or by retrofitting the provisional to the working cast.

Implant Necks

The standard-neck ITI implant is 4.8 mm wide at the implant shoulder and comes in a 4.1-mm solid screw, a 3.3-mm solid screw, a 4.1-mm TE solid screw, and a 3.3-mm TE solid screw. All restorative

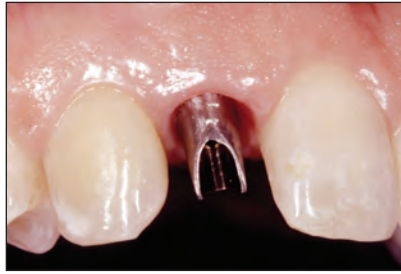
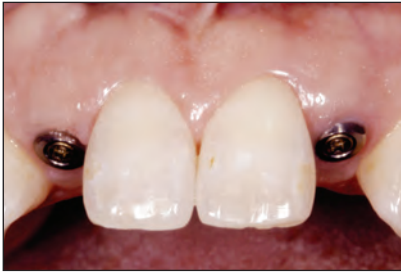

Fig 19a (Left) Two narrow neck implants (NNI) at the end of a 12-week healing period.

Fig 19b (Right) Right custom abutment seated in the mouth with 1.8-mm occlusal screw tightened to 35 Ncm.

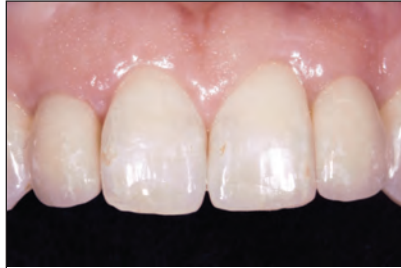
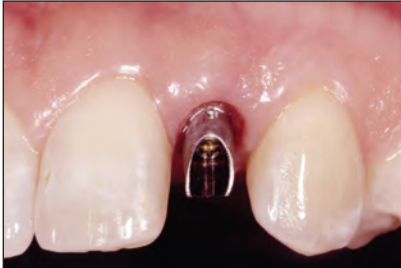
Fig 19c (Left) Left custom abutment seated in the mouth with 1.8-mm occlusal screw tightened to 35 Ncm.

Fig 19d (Right) Definitive porcelain-fused-to-metal cemented restorations in place.

options are standardized for any of the implant bodies. All components are interchangeable. It is vital that great flexibility be available in the option to not select and place a definitive abutment at the time of initiation of the restorative procedure. Therefore, an implant-level impression and laboratory selection of components are recommended if the solid abutment is not used.

The narrow-neck implant (NNI) has a neck dimension of 3.5 mm on a 3.3-mm solid screw. It is used in missing tooth gaps of 7 mm or less. Restoration of the NNI is initiated at 12 weeks after placement. The use of early loading protocols is not recommended with the NNI. The restorative procedure is initiated with an implant-level impression. Impressions may be made with a screw-retained coping for open-tray impressions or a snap coping for simplified closed-tray impressions. Components used to affix restorations to NNI include a 9-mm titanium coping, an oxidizing gold coping for porcelain application, a nonoxidizing gold coping for fabrication of custom abutments, and a 15-degree angled abutment. In most instances a restoration on the NNI is cemented over one of these abutments or copings. In some instances, conditions may be optimal for screw retention using one of the NNI gold copings as a basis for a screw-retained crown. These situations are few because of the anatomic restrictions of such a small restoration. For routine use, the titanium coping is recommended for fabrication of both provisional and definitive restorations. Each of these components allows for customization by the clinician or technician to control the cement line and to accomplish angulation changes. The screw used to

attach abutments and copings to the NNI is a titanium alloy screw 1.8 mm in diameter. The chosen abutment should be torqued to 35 Ncm at the time the definitive restoration is placed. If the implant is placed into function at 12 weeks, the provisional abutment should only be hand tightened. Definitive restorations may be seated with provisional cement; this way, if the occlusal screw securing the abutment should loosen, the crown could be removed to allow retightening of the NNI occlusal screw (Figs 19a to 19d).

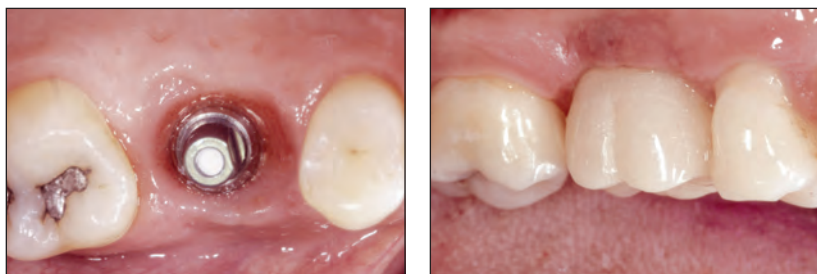There are probably few instances that will allow the use of the wide-neck implant (a 4.8-mm solid screw) with the 6.5-mm top TE implant. In those special instances requiring the 6.5-mm top, it is used with the same components that are available for the standard 6.5-mm-shoulder implant (Figs 20a and 20b).

Definitive Restorative Materials

The standard restoration for an implant-supported prosthesis is the porcelain-fused-to-high-noble-metal restoration (PFM). There is usually sufficient space to allow for adequate thickness of metal, opaque, and ceramic materials in the fabrication of natural-appearing restorations. All-ceramic restorations using aluminous or zirconia cores are also possible, especially for application with porcelain abutments. Anterior teeth and premolars can be restored without considerable risk. However, for molar implant reconstructions, the ceramic cores need to be designed very carefully to provide adequate support for layering porcelains. Failure to do this will lead to porcelain fractures.

Fig 20a (Left) Occlusal view showing the shaped peri-implant tissues.

Fig 20b (Right) Definitive emergence profile restoration cemented into place.



Occlusal Considerations

Occlusal contacts for implant restorations should follow the same principles as those for natural teeth. There should be consecutive contact between centric relation and centric occlusion. The anterior restorations, while in contact, should be slightly less than the posterior contacts by thickness of 1 piece of shim-stock. In lateral movements of the mandible, the anterior teeth should disclude the posterior teeth immediately. Lateral guidance is permissible for anterior implant restorations, if provided by good design. Implant restorations do not need to be removed from contact in lateral excursions. Guidance on anterior implant restorations should not be steep or severe and should be shared by adjacent teeth or implants whenever possible. Although there is no precise definition of overload, it is generally thought that severe forces on dental implants are destructive.^{36,37}

Certainly it is not desirable for any tooth or implant to be in hyperocclusion. Implant restorations in the anterior region need to make contact in centric relation. Contact in centric relation should be less than the posterior contacts by the amount of one piece of shim-stock.

CONCLUSIONS

There is particular concern today that a single-stage or nonsubmerged implant system used in esthetic areas may not be as predictable as clinicians would want. Throughout the course of development of the ITI Dental Implant System, there has been a major emphasis on reaching the utmost limits of what is possible.³⁸⁻⁴¹ The ITI group has stressed simplicity with the use of sound scientific principles and by making the restorative process more user-friendly. However, no clinician would consider restoring the esthetic zone a simple treatment.⁴² This group has attempted to recommend standards for prosthetic treatment in esthetic areas. However, not all individual situations can be addressed. Therefore, every

practitioner needs to be familiar with the basic principles outlined in this document. When basic protocols for treatment are followed, outcomes become more predictable. Armed with knowledge of principles and protocols, clinicians can make informed decisions that will increase their chances of treating each individual patient with success.

ACKNOWLEDGMENTS

Special thanks are extended to the members of the consensus committee on treatments in esthetic areas.

REFERENCES

- Higginbottom FL, Wilson TG. Three-dimensional templates for placement of root-form dental implants. *Int J Oral Maxillofac Implants* 1996;6:787-795.
- Higginbottom FL, Wilson TG. Successful implants in the esthetic zone. *Tex Dent J* 2002;119:1000-1005.
- Sullivan RM. Perspectives on esthetics in implant dentistry. *Compend Contin Educ Dent* 2001;22:685-695; quiz 694.
- Garber DA, Belser UC. Restoration-driven implant placement with restoration-driven site development. *Compend Contin Educ Dent* 1995;16:796-804.
- Laney WR. The emphasis on esthetics [editorial]. *Int J Oral Maxillofac Implants* 2001;16:625.
- Spielman HP. Influence of the implant position on the aesthetics of the restoration. *Pract Aesthet Dent* 1996;8:897-904; quiz 906.
- Buser D, Dula K, Belser U, Hirt HP, Berthold H. Localized ridge augmentation using guided bone regeneration. I. Surgical procedure in the maxilla. *Int J Periodontics Restorative Dent* 1993;13:29-45.
- Goldberg PV, Higginbottom FL, Wilson TG. Periodontal considerations in restorative and implant therapy. *Periodontol 2000* 2001;25:100-109.
- Phillips K, Kois JC. Aesthetic peri-implant site development. The restorative connection. *Dent Clin North Am* 1998;42:57-70.
- Salama H, Salama M, Garber DA. Techniques for developing optimal peri-implant papillae within the esthetic zone. I. Guided soft tissue augmentation: The three-stage approach. *J Esthet Dent* 1995;7:3-9.
- Kois JC, Kan JY. Predictable peri-implant gingival aesthetics: Surgical and prosthodontic rationales. *Pract Periodontics Aesthet Dent* 2001;13:691-698; quiz 700, 721-722.

12. Wong KM, Yuodelis RA, Heindl H. Aesthetic tooth replacement using osseointegrated implants: Pontic and immediate implant site development. *Pract Periodontics Aesthet Dent* 2003;15:45-47.
13. Hermann J, Cochran DL, Nummikowski PV, Buser D. Crestal bone changes around titanium implants. A radiographic evaluation of unloaded nonsubmerged and submerged implants in the canine mandible. *J Periodontol* 1997;68:1117-1130.
14. Davarpanah M, Martinez H, Celletti R, Tecucianu JF. Three-stage approach to aesthetic implant restoration: Emergence profile concept. *Pract Aesthet Dent* 2001;13:761-767; quiz 768, 721-722.
15. Laney WR, Torsten J, Harris D, et al. Osseointegrated implants for single-tooth replacement: Progress report from a multicenter prospective study after 3 years. *Int J Oral Maxillofac Implants* 1994;9:49-54.
16. Levine RA, Clem DS, Wilson TG, Higginbottom FL, Saunders SI. A multicenter retrospective analysis of the ITI Implant System used for single-tooth replacement: Preliminary results at 6 or more months of loading. *Int J Oral Maxillofac Implants* 1997;12:237-242.
17. Levine RA, Clem DS, Wilson TG, Higginbottom FL, Solnit G. A multicenter retrospective analysis of the ITI Implant System used for single-tooth replacements: Results of loading for 2 or more years. *Int J Oral Maxillofac Implants* 1999;14:516-520.
18. Jemt T, Laney WR, Harris D, et al. Osseointegrated implants for single tooth replacement: A 1-year report from a multicenter prospective study. *Int J Oral Maxillofac Implants* 1991;6:29-36.
19. Haas R, Mensdorff-Pouilly N, Mailath G, Watzek G. Bråne-mark single tooth implants: A preliminary report of 76 implants. *J Prosthet Dent* 1995;73:274-279.
20. Belser U, Mericske R, Buser D, Bernard JP, Hess D, Martinet JP. Preoperative diagnosis and treatment planning. In: Schroeder A, Sutter F, Buser D, Krekeler G (eds). *Oral Implantology. Basics, ITI Dental Implant System*, ed 2. New York: Thieme Medical, 1996:231-255.
21. Belser UC, Mericske-Stern R, Bernard JP, Taylor TD. Prosthetic management of the partially dentate patient with fixed implant restorations. *Clin Oral Implants Res* 2000;11(suppl 1):126-145.
22. Belser U, Bernard JP, Buser D. Implant-supported restorations in the anterior region: Prosthetic considerations. *Pract Periodontics Aesthet Dent* 1996;8(9):857-883.
23. Belser U, Buser D, Hess D, Schmid B, Bernard JP, Lang K. Aesthetic implant restorations in partially edentulous patient: A critical appraisal. *Periodontol* 2000 1998;17:132-150.
24. Tarnow DP, Eskow RN. Preservation of implant esthetics: Soft tissue and restorative considerations. *J Esthet Dent* 1996;8:12-19.
25. Tarnow DP, Magner AW, Fletcher P. The effect of the distance from the contact point to the crest of bone on the presence or absence of the interproximal dental papilla. *J Periodontol* 1992;63:995-996.
26. Van Dooren E. Management of soft and hard tissue surrounding dental implants: Aesthetic principles. *Pract Periodontics Aesthet Dent* 2000;12:837-841.
27. Magne P, Magne M, Belser UC. Natural and restorative oral esthetics. Part III. Fixed partial dentures. *J Esthet Dent* 1994;6:15-22.
28. Markus SJ. Interim esthetic restorations in conjunction with anterior implants. *J Prosthet Dent* 1999;82:233-236.
29. Schar AR, Merz BR. *Mechanics of the Synocta Implant/Abutment Connection*. Waldenburg, Switzerland: Institut Straumann, 1999.
30. Keith SE, Miller BH, Woody RO, Higginbottom FL, Nunn ME. Marginal discrepancy of screw-retained and cemented metal-ceramic crowns on implant abutments. *Int J Oral Maxillofac Implants* 1999;14(3):369-378.
31. Hebel KS, Gajjar RC. Cement-retained versus screw-retained implant restorations: Achieving optimal occlusion and esthetics in implant dentistry. *J Prosthet Dent* 1997;77:28-35.
32. Sadan A. Cement considerations for implant-supported restorations. *Pract Periodontics Aesthet Dent* 2000;12:356-363.
33. Kaiser DA, Jones JD. Provisionalization for a single cementable dental implant restoration. *J Prosthet Dent* 1999;81:729-730.
34. Vogel RC. Enhancing implant esthetics with ideal provisionalization. *J Indiana Dent Assoc* 2002;81(3):11-14.
35. Chee WW. Provisional restorations in soft tissue management around dental implants. *Periodontol* 2000 2001;27:139-147.
36. Isidor F. Loss of osseointegration caused by occlusal load of oral implants. A clinical and radiographic study in monkeys. *Clin Oral Implants Res* 1997;7:143-152.
37. Isidor F. Histologic evaluation of peri-implant bone at implants subjected to occlusal overload or plaque accumulation. *Clin Oral Implants Res* 1997;8:1-9.
38. Merz BR, Hunenbart S, Belser U. Mechanics of the implant-abutment connection: An 8-degree taper compared to a butt joint connection. *Int J Oral Maxillofac Implants* 2000;15:519-526.
39. Sutter F, Weber H, Sorenson J, Belser U. The new restorative concept of the ITI dental implant system: Design and engineering. *Int J Periodontics Rest Dent* 1993;13:409-431.
40. Scacchi M. The development of the ITI Dental Implant System. Part 1: A review of the literature. *Clin Oral Implants Res* 2000;11(suppl):8-21.
41. Scacchi M, Merz BR, Schar AR. The development of the ITI Dental Implant System. Part 2: 1998-2000: Steps into the next millennium. *Clin Oral Implants Res* 2000;11(suppl):22-32.
42. Lee EA, Jun JK. Management of complex implant aesthetics: Ensuring restorative design continuity with a comprehensive outcome-based strategy. *Pract Periodontics Aesthet Dent* 2001;13:515-523; quiz 524.